

Received: 2020.04.03

Accepted: 2020.07.09

Available online: 2021.02.01

Published: 2021.XX.XX

Ebstein's Anomaly: An Unanticipated Differential Diagnosis of Egg-on-Stick Appearance and the Diagnostic Dilemma

Authors' Contribution:

Study Design A
Data Collection B
Statistical Analysis C
Data Interpretation D
Manuscript Preparation E
Literature Search F
Funds Collection G

ABDEF **Hayatu Umar**
ACDEF **Usman Muawiyya Zagga**
ABDEF **Femi Akintodun Akintomide**
ADEF **Abubakar S. Maiyaki**
ADEF **Musa Tambuwal Umar**
ADEF **Nasiru Altine Dankiri**
ADEF **Shamsudeen Yusuf**

Department of Internal Medicine, Usmanu Danfodiyo University Teaching Hospital,
Sokoto, Nigeria

Corresponding Author: Hayatu Umar, e-mail: drhiatoo@gmail.com
Conflict of interest: None declared

Patient: Female, 42-year-old
Final Diagnosis: Ebstein's anomaly
Symptoms: Dyspnoea on exertion • early satiety • fatigue • orthopnea • PND • progressive abdominal swelling • weigh loss
Medication: —
Clinical Procedure: Paracentesis
Specialty: Cardiology


Objective: Rare co-existence of disease or pathology
Background: Ebstein's anomaly (EA) is a rare congenital cardiac abnormality with diverse anatomic and spectra of clinical presentations. This heart anomaly occurs in approximately 1 per 200 000 live births and accounts for <1% of congenital cardiac diseases. The main pathologic finding is "atrialization" of the basal region of the right ventricle. EA has been described extensively in the literature; however, to the best of our knowledge, this is the first reported case of EA presenting with "egg-on-stick" appearance.

Case Report: A 42-year-old woman presented on account of 2 years of progressive abdominal swelling, early satiety, and progressive weight loss. There was an associated history of dyspnea on exertion, easy fatigability, paroxysmal nocturnal dyspnea, and orthopnea. General examination revealed egg-on-stick appearance: visible distended abdominal wall veins and massive ascites with no pedal edema. Overall, pertinent cardiovascular examination findings and echocardiographic features are in keeping with EA.

Conclusions: We present the likely first case of egg-on-stick appearance as part of the presentation of EA, which posed a diagnostic dilemma. Echocardiography can help in unraveling this dilemma.

Keywords: Diagnosis, Differential • Ebstein Anomaly • Echocardiography

Full-text PDF: <https://www.amjcaserep.com/abstract/index/idArt/924810>



1818



1



3



7



Background

Ebstein's anomaly (EA) is a rare congenital cardiac abnormality with diverse anatomic and spectra of clinical presentations. This heart anomaly occurs in approximately 1 per 200,000 live births, accounting for <1% of congenital cardiac diseases [1]. EA and tricuspid atresia are the most significant congenital pathologic anomalies that affect the tricuspid valve. This cardiac entity is characterized by a variable degree of apical displacement of septal or posterior (or both) leaflets of the tricuspid valve into the right ventricle. This results in "atrialization" of the basal region of the right ventricle as its orifice is displaced upward in relation to the anatomic annulus [2]. The anomalies in EA range from insignificant displacement of the leaflets to a muscular shelf between the trabecular transition zones and inlet of the right ventricle to an imperforate membrane. The clinical features are dependent on the malformation of the valve and regurgitation in addition to other accompanied heart defects [3]. Apical 4 chamber is the preferred echocardiographic view for evaluation [2]. Patients may present with either features of right-sided or eventually biventricular heart failure [4]. Furthermore, there may be cyanosis, paradoxical embolism, arrhythmias, and eventually sudden cardiac death. Although many patients may experience first symptoms in adulthood, symptoms may also occur after birth, during infancy, or during childhood [4]. EA has been described extensively in the literature; however, to the best of our knowledge, this is the first reported case of EA presenting with egg-on-stick appearance.

Egg-on-stick is a typical body habitus characterized by markedly distended abdomen, which may be due to gross ascites or truncal obesity or an abdominopelvic mass that is disproportionate to the size of the lower limbs (very thin legs) with little or no pedal edema. This typical appearance of egg-on-stick is usually seen in right-sided endomyocardial fibrosis (EMF) and Cushing syndrome. Others include right atrial myxoma mimicking restrictive cardiomyopathy [5], decompensated liver cirrhosis with or without cirrhotic cardiomyopathy, constrictive pericarditis, malignant ovarian cyst, huge ovarian cyst, Meigs syndrome, abdominal tuberculosis (ascitic type), intestinal schistosomiasis with portal hypertension, and hyperimmune reactive malarial splenomegaly syndrome.

Case Report

A 42-year-old woman was referred to our hospital on account of 2 years of progressive abdominal swelling, early satiety, and progressive weight loss. There was associated history of dyspnea on mild to moderate exertion, easy fatigability, occasional dry cough, paroxysmal nocturnal dyspnea, and orthopnea. She volunteered a history of recurrent palpitations that

dated back to early childhood, though no accompanying dizziness or syncopal attack. The patient did not remember having any symptoms suggestive of rheumatic fever, preferential squatting, or recurrent cyanotic spells during childhood. She was seen in both a primary health-care center and a general hospital several times on account of presenting complaints and was given several medications that included diuretics, but with no remarkable improvement. Before our clinical evaluation, she was diagnosed with Meigs syndrome, a malignant ovarian cyst, and decompensated liver cirrhosis.

On examination, she was chronically ill-looking, in obvious respiratory distress with a respiratory rate of 28 cycles/min, icteric, acyanotic; temperature was 37.2°C, no digital clubbing or significant peripheral lymphadenopathy, no periorbital or pedal edema, no peripheral stigmata of chronic liver disease, and a striking egg-on-stick appearance (**Figure 1A, 1B**). She weighed 42 kg with a height of 156 cm and a body surface area (BSA) of 1.34 m². The pertinent cardiovascular system findings were: pulse rate 112 beats/min (bpm), blood pressure 120/70 mmHg, jugular venous pressure elevated to the angle of the jaw, precordium hyperactive, and the apex at 5 left intercostal space, 3 cm lateral to mid-clavicular line with left parasternal heave, and heart sounds first (S1) and second (S2) with loud pulmonary component of S2, 2/6 pansystolic murmur best heard at the left lower border of the sternum, with inspiratory accentuation and bibasal posterior fine crepitations. Abdominal examination revealed visible distended abdominal veins draining upward (below and above the umbilicus), massive ascites demonstrated by fluid thrill, and hepatomegaly demonstrated by ballottement. The laboratory results are as documented in the **Table 1**. Chest X-ray showed cardiomegaly, unfolded aorta, hilar vessel engorgement with upper-lobe blood diversion, superior vena cava prominent, no lung parenchymal lesion seen, costophrenic angles free, and elevation of the right hemidiaphragm in keeping with ascites in the upper abdomen (**Figure 2**). Electrocardiogram showed sinus rhythm with heart rate of 86 bpm, normal axis, ST-T wave abnormality in V3-V5, and no atrial enlargement or ventricular hypertrophy. Echocardiography showed normal-size left atrium with diameter of 38.28 mm, right atrium (RAID) with diameter of 44.06 mm (RAID minor axis/BSA=3.29cm/m² indicates severely dilated right atrium), and right ventricle diameter of 33.69 mm. The left ventricle was normal and end-diastolic and -systolic diameters were 38.50 mm and 26.95 mm respectively. An apical 4-chamber view showed (**Figure 3**) leaflets of tricuspid valve displaced apically into the right ventricle, with a distance of 11.39 mm (9 mm/m²) between the mitral valve plane and the septal leaflet. Systolic tethering of the posterior and septal leaflets of the tricuspid valve resulting in failure of central coaptation and severe regurgitation was noted. Other heart valves were normal in motion and morphology; no intramural thrombus or echogenic mass obliterating the apices of

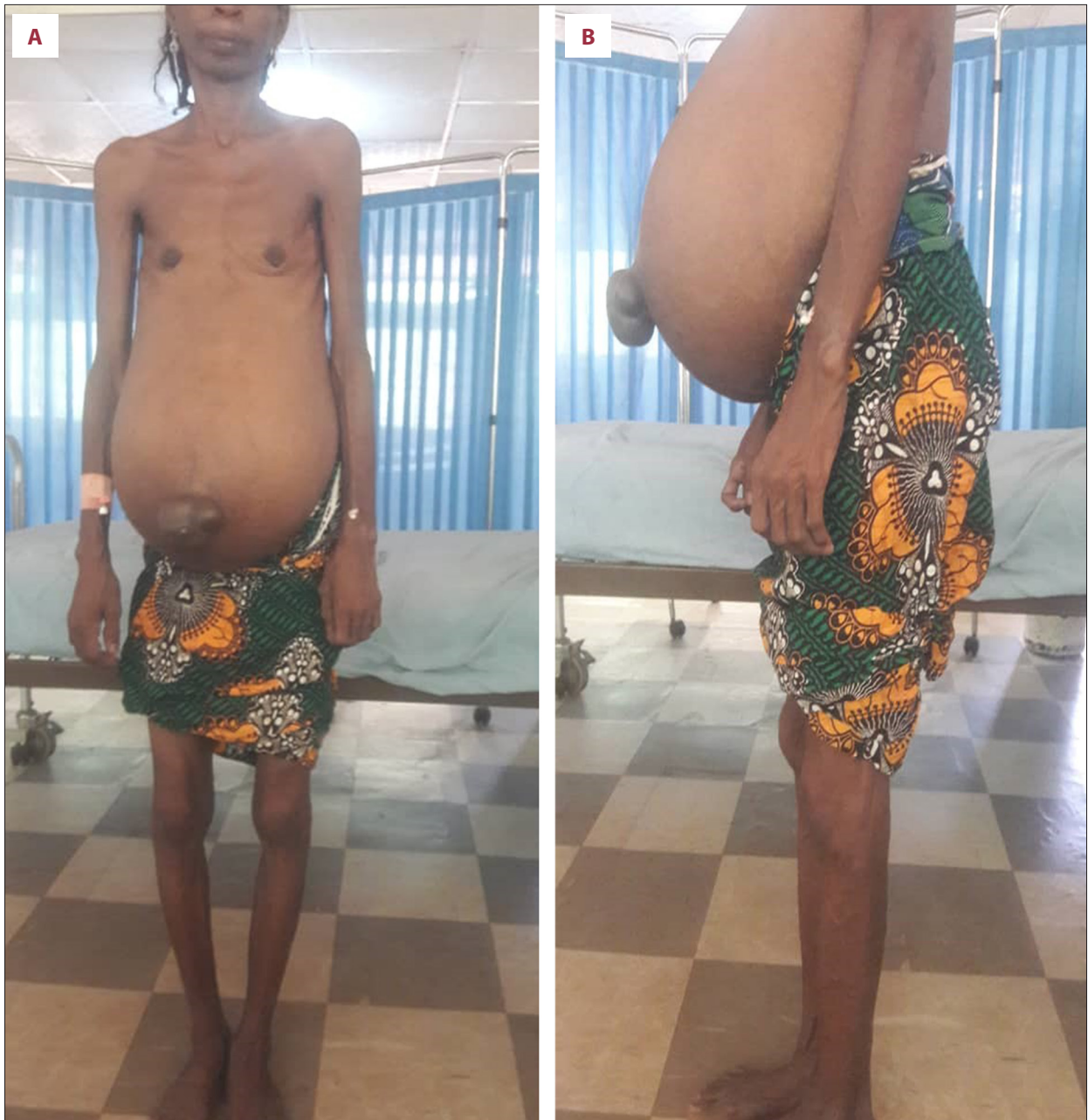

Figure 1. (A, B) Typical egg-on-stick appearance of index case. Markedly distended abdomen with visible distended superficial veins and gross ascites that is disproportionate to the size of lower limbs (very thin legs) with no pitting edema.

ventricular chambers was seen. The LV ejection fraction was 66% and fractional shortening was 30%, transmitral early/late ratio of 1.9, deceleration time of 150 ms, and isovolumetric relaxation time of 55 ms. Severe tricuspid regurgitation with tricuspid valve regurgitant jet area of $>10 \text{ cm}^2$ and mild mitral and pulmonary regurgitation with pulmonary arterial systolic pressure of 40 mmHg at rest were also seen. No other anomalies were noted. Cardiac magnetic resonance imaging is not available in our center. After a multidisciplinary review, a diagnosis of EA complicated by heart failure was made. She was

placed on spironolactone, a diuretic, captopril, therapeutic abdominal paracentesis, and nutritional rehabilitation, and she was subsequently advised for surgical repair.

Discussion

EA is a rare complex congenital cardiac abnormality first reported by Wilhelm Ebstein in 1866 [6]. The main pathologic finding of EA is apical displacement of the tricuspid septal leaflet

Table 1. Laboratory parameters of our index case.

| S/N | Investigations | Results | Normal values |
|-----|----------------------------|------------------------|-----------------------------|
| 1. | Liver function tests | | |
| | Aspartate aminotransferase | 64 | 26-34 U/L |
| | Alanine aminotransferase | 48 | 26-34 12 U/L |
| | Alkaline phosphatase | 380 | 98-279 U/L |
| | Total bilirubin | 2.29 | Up to 1.2 mg/dL |
| | Direct bilirubin | 0.36 | Up to 0.25 mg/dL |
| | Total protein | 6.0 | 6.0-8.0 g/dL |
| | Albumin | 3.1 | 3.5-5.0 g/dL |
| 2. | WBC | 7.0×10 ⁹ /L | 4.0-10.0×10 ⁹ /L |
| | Platelets | 140×10 ⁹ /L | 100-300×10 ⁹ /L |
| | Hemoglobin | 14.4 g/dL | 11.0-16.0 g/dL |
| 3. | Electrolytes | | |
| | Na | 141 | 135-149 mmol/L |
| | Cl | 99 | 96-106 mmol/L |
| | K | 4.1 | 3.5-5.2 mmol/L |
| | Bicarbonate | 24 | 21-31 mmol/L |
| | Urea | 3.6 | 2.5-6.5 mmol/L |
| | Creatinine | 0.4 | 0-1.3 mg/dL |
| 4. | HBsAg and anti-HCV | Nonreactive | |
| 5. | HIV serology | Nonreactive | |

WBC – white blood cells; HbsAg – hepatitis B surface antigen; HCV – hepatitis C; HIV – human immunodeficiency virus.

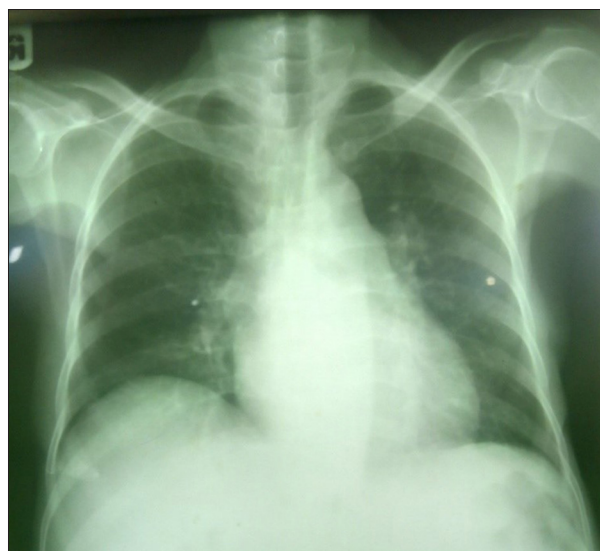

Figure 2. Chest X-ray of the patient.

by a minimum of 8 mm/m² [7], and that of our patient was 9 mm/m². The clinical features of EA are diverse and sometimes evasive. Right ventricular failure is the usual presentation in pediatrics, whereas adults present with right ventricular failure and dysrhythmia as seen in our patient [4]. No 2 patients with EA have a similar pattern of clinical presentation. Our patient was followed by multiple specialists: a general practitioner and a gynecologist entertained the possibility of Meigs

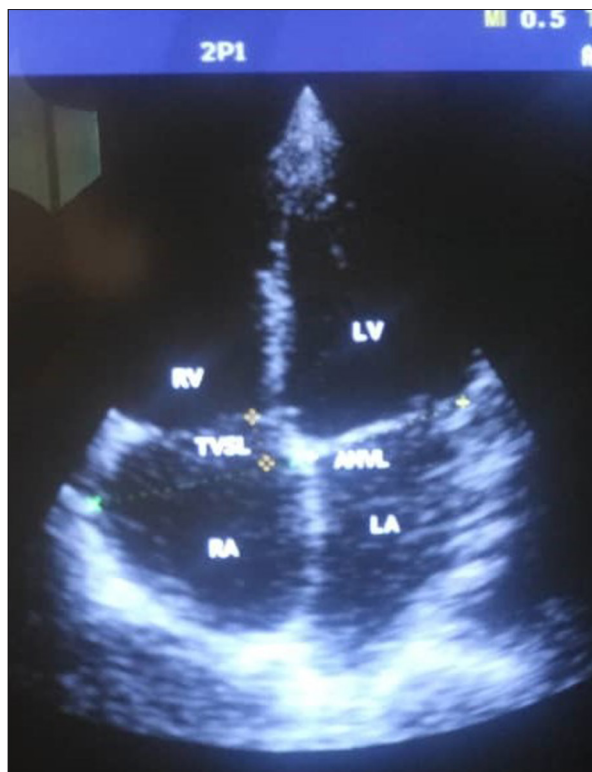

Figure 3. Displaced leaflets of tricuspid valve apically in apical 4-chamber view.

syndrome and malignant ovarian cyst. However, after further evaluation and examination of findings by the gastroenterologist, decompensated liver cirrhosis and a differential diagnosis of right-sided heart failure was considered. The diagnosis of EA was established by the cardiologist after history, examination, and investigations, especially echocardiography.

EA may pose a diagnostic dilemma with other diseases that may present as egg-on-stick appearance, such as EMF and atrial myxoma [5]. Nevertheless, echocardiographic findings differ, and thus may assist in differentiating the various pathologies specific to each disease state.

Idiopathic pulmonary arterial hypertension (IPAH) is a diagnosis of exclusion. IPAH complicating right-sided heart failure may be a differential diagnosis in this index case, being more common in women. Although dyspnea, cough, easy fatigue, recurrent dizziness, and syncopal attacks might be the earliest presenting symptoms, which are subsequently followed by symptoms of right-sided heart failure, there may be a family history of similar presenting symptoms. In contrast, our index case presented with initial symptoms of right-sided heart failure associated with recurrent palpitations that dated back to childhood, which was subsequently followed by symptoms of left-sided heart failure. Even though a pulmonary function test and right heart catheterization were not carried out in this patient, and although echocardiography revealed pulmonary arterial hypertension, other echocardiographic findings are in keeping with EA, so this ruled out IPAH.

A malignant ovarian cyst, huge ovarian cysts, and Meigs syndrome may present clinically with egg-on-stick appearance because all can have ovarian cysts of variable sizes with or without ascites. However, what ruled against this gynecologic condition in our patient were the pertinent cardiovascular findings, ascites demonstrable by fluid thrill, ultrasound findings of congestive hepatomegaly with ascites in the absence of ovarian cysts, chest X-ray findings of cardiomegaly, and cardiogenic pulmonary edema. Meigs syndrome is a diagnosis of exclusion, with a triad of pleural effusion, ascites, and benign ovarian fibroma. Therefore, these gynecological conditions are unlikely in this index case.

Decompensated hepatic cirrhosis in the presence or absence of cirrhotic cardiomyopathy is a plausible diagnostic consideration of egg-on-stick appearance. Even though our patient presented with progressive abdominal swelling, easy satiety, weight loss, and examination finding of jaundice, there was no associated abdominal pain, hematemesis, generalized skin pruritus, and peripheral stigmata of chronic liver disease. Furthermore, classic symptoms and signs suggestive of left-sided heart failure are hardly seen in patients with decompensated liver cirrhosis except if there are associated complications such as cirrhotic cardiomyopathy and severe anemia, although dyspnea may be seen because of gross ascites, hepatopulmonary syndrome, high-output heart failure,

or anemia. In addition, orthopnea may also be seen because of massive ascites. Ultrasound may reveal a large or shrunken liver with distorted and coarsened parenchymal architecture but not congestive hepatomegaly, as seen in the index case.

Cushing syndrome, an endocrine disorder, may present with egg-on-stick appearance, but what rules against this syndrome in our index case is absence of moon facie, buffalo hump, no history, and physical findings of proximal myopathy, body striae, and truncal obesity.

Constrictive pericarditis complicating biventricular heart failure may be a differential diagnosis of egg-on-stick appearance, but in this condition, there may be past history suggestive of pulmonary tuberculosis, low-grade continuous or high-grade fever resulting from acute bacterial or viral pericarditis and chest pain, history suggestive of autoimmune rheumatic disease, radiation exposure, use of medications causing pericarditis, kidney disease, or heart surgery, which are absent in our index case.

Other less commonly seen clinical conditions that may present with egg-on-stick appearance include hyperimmune reactive malarial splenomegaly syndrome, intestinal schistosomiasis with portal hypertension, and abdominal tuberculosis (ascitic type). Therefore, detailed history, clinical examination, and case-directed investigations may assist in ruling them out.

Conclusions

We present the likely first case of egg-on-stick appearance as part of the presentation of EA, which posed a diagnostic dilemma. Multispecialty review helped in arriving at a definitive diagnosis of this clinical condition, thereby averting misdiagnosis and its potential consequences. EA should be considered whenever egg-on-stick appearance is encountered in an adult.

Thus, the learning points in this case report are as follows: (1) EA is a diagnostic consideration of egg-on-stick appearance, and (2) diagnosis in a patient presenting with egg-on-stick appearance may occasionally be challenging; however, multispecialty review may aid in unraveling the definitive diagnosis. Echocardiography has an important diagnostic role in these patients, especially in poor resource settings like ours.

Acknowledgment

We acknowledge the patient for her cooperation and for giving us consent for this case report.

Conflict of Interest

None.

References:

1. Attenhofer Jost CH, Connolly HM, Edwards WD, et al. Ebstein's anomaly – review of a multifaceted congenital cardiac condition. *Swiss Med Wkly.* 2005;135:269-81
2. Armstrong WF, Ryan T, Feigenbaum H. Feigenbaum's echocardiography. 7th ed. Philadelphia: Wolters Kluwer Health/Lippincott Williams & Wilkins; 2010
3. Webb GD, Smallhorn JF, Therrien J, et al. Chap. 75: Congenital heart disease in the adult and pediatric patient. In: Zipes DP, Libby P, Bonow RO et al. (eds.), *Braunwald's heart disease: A textbook of cardiovascular medicine.* 11th ed. Philadelphia, PA: Elsevier; 2019;1519-73
4. Celermajer DS, Bull C, Till JA, et al. Ebstein's anomaly: Presentation and outcome from fetus to adult. *J Am Coll Cardiol.* 1994;23(1):170-76
5. Muawiyya ZU, Hayatu TU, Isah O, Isezuo SA. A probable case of right atrial myxoma presenting with features of restrictive cardiomyopathy. *Kanem J Med Sci.* 2019;13(2):1-4
6. Mazurak M, Kusa J. The two anomalies of Wilhelm Ebstein. *Texas Hear Inst J.* 2017;44(3):198-201
7. Edwards WD. Embryology and pathologic features of Ebstein's anomaly. *Prog Pediatr Cardiol.* 1993;2(1):5-15