

Received: 2020.07.28

Accepted: 2021.01.12

Available online: 2021.02.04

Published: 2021.XX.XX

Chronic Headache and Cerebral Venous Sinus Thrombosis Due to Varicella Zoster Virus Infection: A Case Report and Review of the Literature

Authors' Contribution:

Study Design A
Data Collection B
Statistical Analysis C
Data Interpretation D
Manuscript Preparation E
Literature Search F
Funds Collection G

ABCDEF 1 **Laith Alamliah**
ABCDEF 2 **Mohammad Abdulgayoom**
ABCEF 2 **Suresh N. Menik Arachchige**
BCE 3 **Mohammed Hamza Shah**
ADE 2,4 **Muhammad Zahid**

1 Rheumatology Section, Department of Medicine, Hamad General Hospital, Doha, Qatar

2 Department of Medicine, Hamad General Hospital, Doha, Qatar

3 Department of Radiology, Hamad General Hospital, Doha, Qatar

4 Weill-Cornell Medicine, Doha, Qatar

Corresponding Author: Laith Alamliah, e-mail: laythamleh@yahoo.com, lamliah@hamad.qa
Conflict of interest: None declared

Patient: Male, 20-year-old
Final Diagnosis: Cerebral venous sinus thrombosis • varicella zoster virus infection
Symptoms: Fever • headache • skin rash
Medication: —
Clinical Procedure: —
Specialty: Infectious Diseases • Rheumatology

Objective: Unusual clinical course

Background: Varicella zoster virus (VZV) infection causes 2 clinically distinct forms of the disease: varicella (chickenpox) and herpes zoster (shingles). Primary VZV infection results in the diffuse vesicular rash of varicella, or chickenpox. Endogenous reactivation of latent VZV typically results in a localized skin infection known as herpes zoster, or shingles.

The infection usually manifests as a self-limited disease. However, it can be associated with various neurological complications such as encephalitis, meningitis, ventriculitis, cerebellar ataxia, ischemic or hemorrhagic, and, rarely, cerebral venous sinus thrombosis (CVST). This report presents a case of cerebral venous sinus thrombosis due to varicella zoster virus infection in a 20-year-old Nepalese man who presented to the Emergency Department with headache.


Case Report: A 20-year-old Nepalese male patient presented to the Emergency Department with headache of 10 day's duration. Five days prior to that, he had a diffuse pruritic skin rash. Examination as well as serology confirmed the presence of primary varicella infection. Computed tomography (CT) and magnetic resonance venography (MRV) demonstrated CVST. Thrombophilia workup revealed a transient elevation of antiphospholipid serology. Shortly after admission, the patient had a transient seizure. He was treated with acyclovir, levetiracetam, and anticoagulation. A comprehensive literature review of similar cases was performed to establish a link between thrombotic complications and primary VZV infection and to formulate possible mechanistic pathways.

Conclusions: This report shows that primary VSV infection can be associated with vasculopathy and CVST. Physicians should recognize this serious complication, which should be diagnosed and treated without delay.

Keywords: Anticoagulants • Antiphospholipid Syndrome • Herpesvirus 3, Human • Sinus Thrombosis, Intracranial

Abbreviations: VZV – varicella zoster virus; CVST – cerebral venous sinus thrombosis; VrCVST – varicella-related CVST; VTE – venous thromboembolism; CT – computed tomography; MRI – magnetic resonance imaging; MRV – magnetic resonance venography; APS – antiphospholipid syndrome; PCR – polymerase chain reaction

Full-text PDF: <https://www.amjcaserep.com/abstract/index/idArt/927699>

 2384

 2

 3

 34

Background

Varicella zoster virus (VZV) is an Alpha-herpesvirus, which is one of the Herpesviridae subfamilies. Infection usually manifests as varicella (chickenpox) or herpes zoster, particularly in older adults [1]. Chickenpox is much more common in children and tends to have a self-limiting course. However, in adults, the disease has more complications and can even lead to death [2,3]. VZV infection is linked to various neurological complications such as encephalitis, meningitis, ventriculitis, cerebellar ataxia, ischemic or hemorrhagic stroke due to arterial vasculopathy, and, rarely, cerebral venous sinus thrombosis (CVST) [4].

CVST is an uncommon causes of stroke, and it usually affects young individuals [5]. In general, the condition is rare and has an incidence of 0.32-1.57 per 100 000 person-years, with a female-to-male ratio of 3: 1 [6,7]. There are various risk factors involved in the development of CVST, including congenital thrombophilia, use of oral contraceptives, autoimmune diseases such as Behçet's disease, and antiphospholipid syndrome, malignancy, and infections [8 9]. Although infectious causes only account for a minority of cases in developed countries, they are of high importance as a cause of CVST in developing countries [10,11]. Infection-induced CVST attributes to 8.1-35.6% of all CVST [9,12]. Varicella infection can cause various thrombotic manifestations; however, the infection is rarely associated with CVST. This report presents a case of cerebral venous sinus thrombosis due to varicella zoster virus infection in a 20-year-old Nepalese man who presented to the Emergency Department with headache. We also provide a detailed literature review of varicella-related CVST (VrCVST).

Case Report

A 20-year-old Nepalese man presented to the Emergency Department with a headache of 10 day's duration. The headache came in severe attacks and was dull aching in nature, mainly over the frontal area. It had no specific aggravating or relieving

factors. The headache was associated with dizziness, nausea, and occasional vomiting. Five days prior to these symptoms, he developed a skin rash and a subjective fever. The patient described the rash as pruritic blister-like small lesions that started over the face and later diffused to involve the trunk and limbs. The fever was more prominent at night and lasted for 3 days. The patient denied any recent travel. However, he stated that he had contact with 3 other roommates who developed a similar skin rash, but they did not seek medical advice. He thought that his roommates had not sought medical attention. Furthermore, there was no history of visual disturbances, photophobia, weakness, seizure, or abnormal behavior. The review of systems was otherwise unremarkable. There was no past medical or surgical history of note. He was not taking any medications regularly and had no prior use of medications. The patient stated that he received childhood vaccines in Nepal, but he is not aware of the details and had no record of them. He had no family history of venous thromboembolism (VTE) or premature cardiovascular events.

On examination, his Glasgow Coma Score was 15/15, blood pressure was 140/90 mmHg, body temperature was 37°C, pulse was 80 beats per minute; respiratory rate was 18 breaths per minute, and SpO₂ was 97%. There were scattered small macules, papules, and vesicles over his face and body. The lesions were not localized to a specific dermatome and were more diffused and bilateral. Most of the lesions were healed, with occasional crusted lesions distributed particularly over his trunk (**Figure 1**). The patient had mild neck stiffness and normal power and reflexes. Results of a sensory exam were normal. He had negative Babinski sign. Cardiac, respiratory, and abdominal exams were unremarkable.

His blood investigations (**Table 1**) revealed a normal complete blood count, renal function, and liver function tests. However, the laboratory test results were positive for varicella zoster IgG and IgM antibodies. HIV (Human Immunodeficiency Virus) screening yielded negative results. We did not assess D-dimer or perform serology for other Herpesviridae or other viral infections. A plain computed tomography (CT) scan of the head

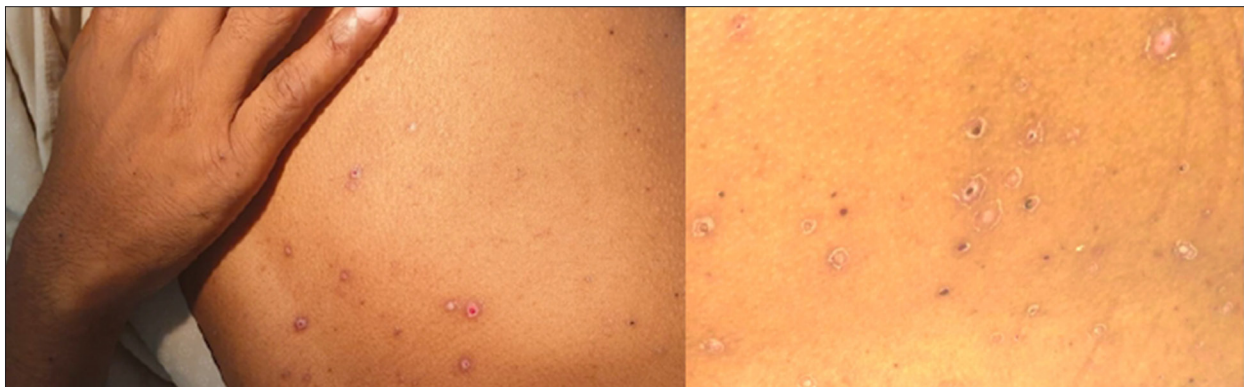

Figure 1. Maculopapular rash and mature vesicles with crusting.

Table 1. Pertinent laboratory results.

Test type	Value	Test type	Value	Test type	Value	Value 2 months later
Urea	3.4 mmol/L	WBC	7.1×10 ³ /ul	Lupus anticoagulant	Positive lupus ratio: 1.64	Negative
Creatinine	65 umol/L	Neutrophil%	75.3%	Protein S Activity	Normal	–
Sodium Na	139 mmol/L	Lymphocyte%	15.7%	Protein C Activity	Normal	–
Potassium K	3.5 mmol/L	Monocyte%	8.6%	Anticardiolipin Ab IgG	Negative 2.2 MPL	Negative 0.6 MPL
Chloride	98 mmol/L	Eosinophil%	0.1%	Anticardiolipin Ab IgM	Positive 64 MPL	Negative 18MPL
Bicarbonate	26 mmol/L	Basophil%	0.3%	Anti B2 Glycoprotein IgG	Weakly positive 20 MPL	Negative 3 MPL
Calcium	2.43 mmol/L	Hemoglobin	13.4 gm/dL	Anti B2 Glycoprotein IgM	Positive 41MPL	Negative 11MPL
Glucose	5 mmol/L	Platelets	172×10 ³ /uL	Factor V Leiden	Negative	–
CRP	11.5 mg/L	Test Type	Value	Rheumatoid Factor	Negative	–
ALT	36 U/L	Varicella Zoster Ab IgG	Positive	Anti CCP Ab	Negative	–
AST	19 U/L	Varicella Zoster Ab IgM	Positive	ANA	Negative	–

was suggestive of CVST, so it was followed with a CT venogram (CTV), which confirmed the presence of extensive CVST involving the cerebral venous sinuses, cortical veins, and proximal left internal jugular vein (Figure 2). Magnetic resonance imaging (MRI) and magnetic resonance venography (MRV) confirmed the finding of CVST. The images also showed a small lacunar infarction and right frontal parenchymal edema, microhemorrhages, and venous cortical-juxta cortical ischemic changes (Figure 3). However, there was no evidence of meningeal enhancement on imaging. Hypercoagulability and autoimmune workup were negative for factor V Leiden, rheumatoid factor, anti-nuclear antibodies, and anti-cyclic citrullinated peptide (anti-CCP) antibodies. Protein C, protein S, and homocysteine levels were normal. However, the antiphospholipid syndrome (APS) workup showed a positive lupus anticoagulant, positive IgM anti-cardiolipin antibodies, positive IgM anti-b2 glycoprotein antibodies, and weakly positive IgG anti-b2 glycoprotein.

Shortly after admission, he was noticed to have attacks of brief lapse of consciousness with staring and irregular movement of his left limb, indicative of focal seizures, which raised the suspicion of the presence of meningoencephalitis. A lumbar puncture was performed successfully after multiple attempts due to inappropriate body habitus, revealing an opening pressure of 28 cmH₂O, and on visual inspection, the sample was blood-tinged. Cerebrospinal fluid (CSF) analysis was done and the

results showed a WBCs of 6/uL (corrected WBC for RBCs was at 4/uL) [normal range 0-5/uL], RBCs of 967/uL [normal range 0-2/uL], CSF glucose 2.91 mmol/L [normal range 2.2-3.9 mmol/L], and CSF protein 0.42 gm/L [normal range 0.15-0.45 gm/L]. The CSF was negative for gram stain, culture, acid-fast bacilli (AFB) smear, tuberculosis polymerase chain reaction (PCR), tuberculosis culture, fungal culture, cryptococcal antigen, and cytology. Due to the difficult lumbar puncture, an insufficient amount of sample was obtained to send for all the investigations. A diagnosis of primary varicella infection was made based on typical clinical manifestations, which were supported by the presence of IgM VZV antibodies. Thus, we did not need to perform an IgG antibody avidity test to differentiate acute from past infection.

The patient was started on intravenous (IV) acyclovir 600 mg Q6 hourly, enoxaparin 80 mg subcutaneous daily (bridging), and warfarin 5 mg daily for the CVST (with an INR target of 2-3) and levetiracetam 500mg twice daily for the focal seizure. At 8 week's follow-up, the patient was doing well and completely asymptomatic. He had stopped the warfarin after about 1 month, stating that he was feeling well and did not have reason to continue. He was counseled on the importance of taking warfarin and the possible complication of non-concordance to it. Two months later, repeated laboratory tests were unremarkable, including for the APS workup, which was negative for lupus anticoagulant as well as for APS antibodies (Table 1).

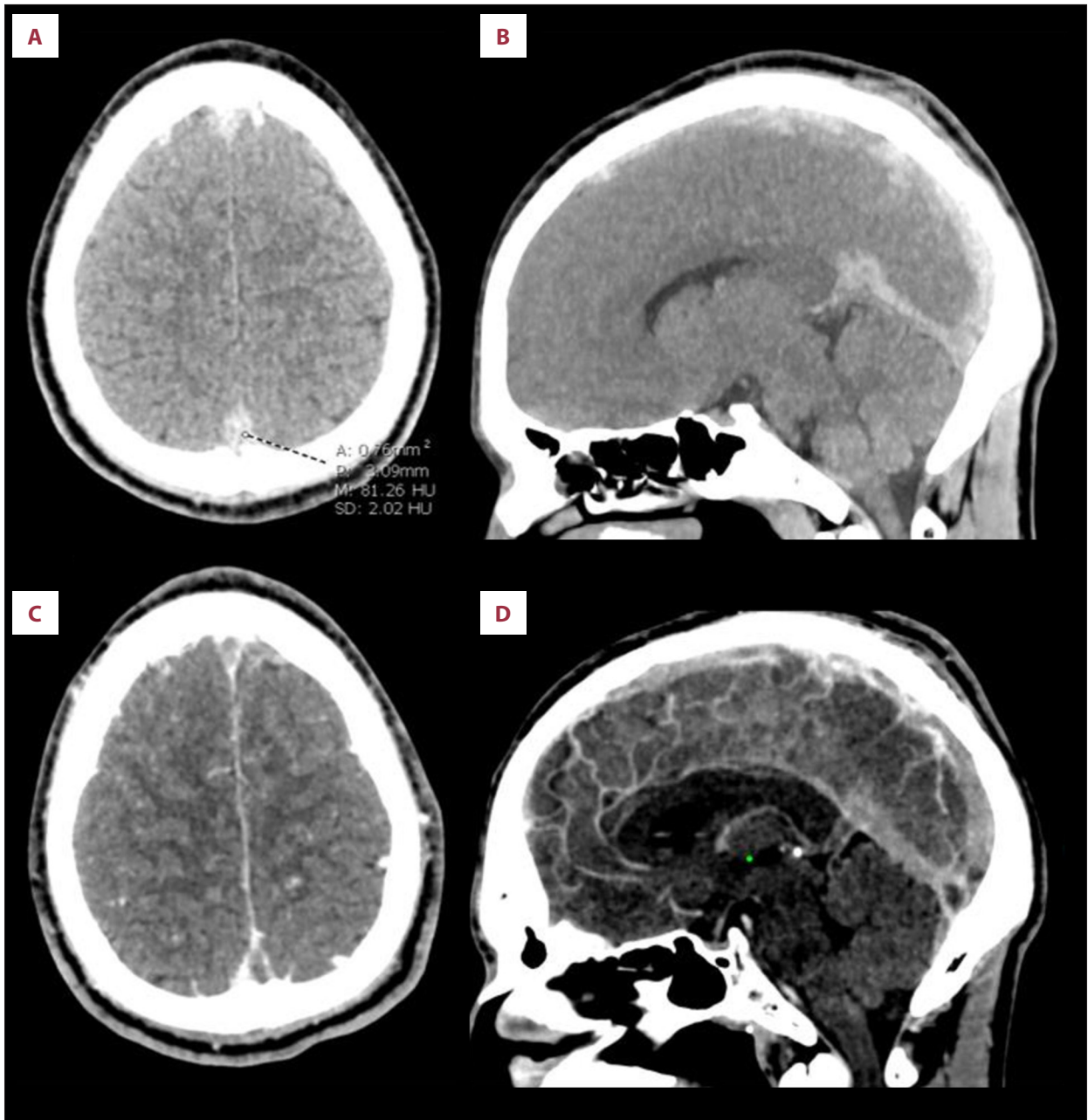

Figure 2. Unenhanced CT brain and contrast-enhanced CT venography. (A) Axial and (B) midline MIP sagittal images from unenhanced CT show hyperdense superior sagittal sinus (CT density of about 80 Hounsfield units), straight sinus and bilateral frontal parasagittal cortical veins concerning for thrombosis. (C) Axial and (D) midline sagittal CT venography images confirm filling defects in the cerebral dural venous sinuses and cortical veins indicative of thrombosis. Thrombosis extended into the transverse and sigmoid sinuses and left internal jugular vein (not shown).

Discussion

This case demonstrates that varicella infection can cause thrombosis by production of antiphospholipid antibodies. The diagnosis of primary varicella infection was made clinically and was confirmed by serology. The CVST was chronologically correlated with varicella and confirmed with MRV. The patient was

found to have transient APS biomarkers; otherwise, all other common congenital and acquired causes of thrombophilia were ruled out. We performed a comprehensive literature review searching for CVST cases related to primary varicella infection. We searched 3 databases – PubMed, Embase (OVID: 1980 to current), and Scopus – to 23 June 2020. A combination of keywords limited to title/abstract field and subject terms

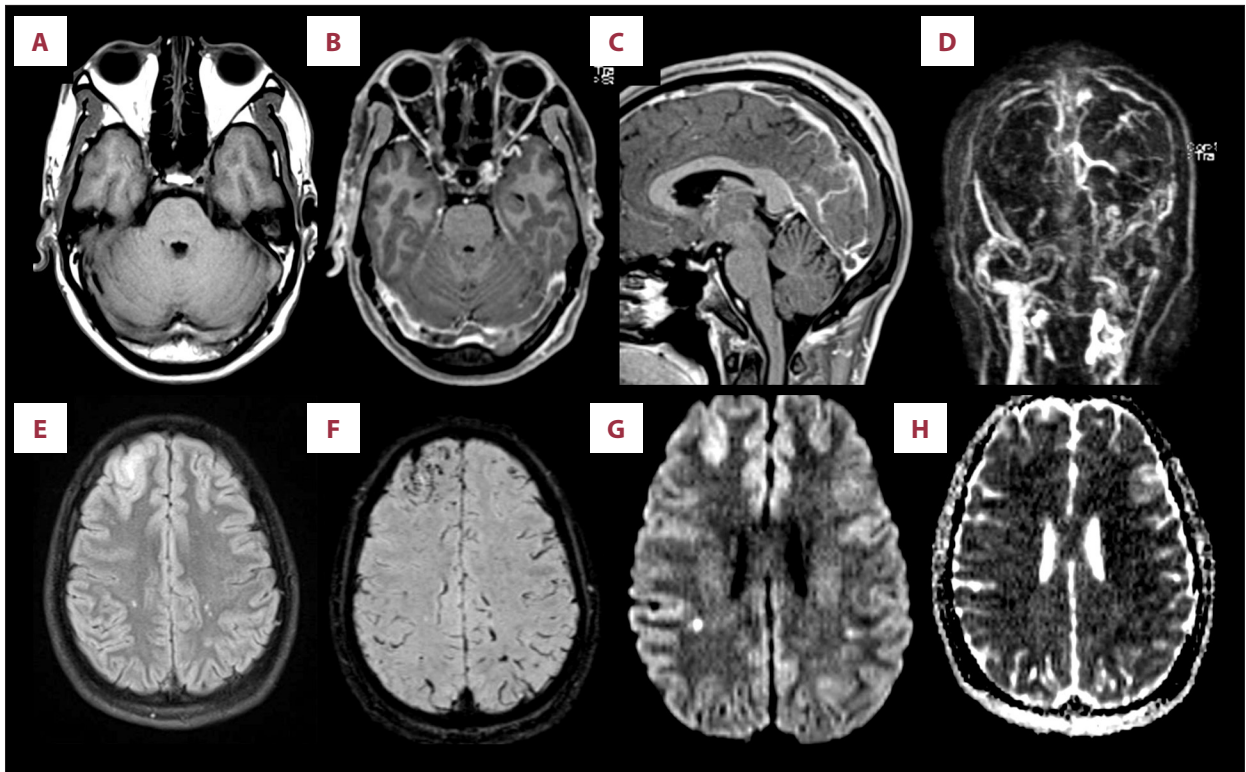


Figure 3. MRI brain including contrast-enhanced MR venography. (A) Axial T1-weighted pre-contrast image shows signal in bilateral transverse sinuses isointense to grey matter. (B) Axial and (C) sagittal T1-weighted post-contrast images confirm filling defects within bilateral transverse sinuses, superior sagittal sinus, and straight sinus. (D) Coronal and (H) sagittal MIP images from MR venography demonstrate extensive thrombosis of the dural venous sinuses extending into the left internal jugular vein. (E) FLAIR image shows small area of cortical and subcortical edema in the right frontal lobe, with presence of microhemorrhages at this site on SWI (F). (G) DWI images show small foci of diffusion restriction within the temporoparietal white matter bilaterally, compatible with acute lacunar infarcts.

were used in the base search. No language or date restrictions were used in any of the searches. We included all case reports of primary varicella infection-related CVST that were similar to our case. We found 11 articles describing 13 patients with VrCVST (Table 2) [13-23]. The condition was found to primarily affect males, contrary to other causes of CVST, which primarily affect females [7]. All patients were young; the age range was 15-39 years, with a mean of 25.8 years and a median of 26 years. This is consistent with the predominance of CVST in the young population. However, patients with VrCVST are younger than CVST patients [9].

Our patient developed manifestations suggestive of CVST (thunderclap headache), about 5 days after the appearance of the skin rash and fever. The CVST was diagnosed 2 weeks after he started to have symptoms. This is consistent with the reported cases, which developed CVST 2-3 weeks after the onset of VZV disease, except for 2 cases in which CVST was diagnosed after 1 week from the presentation of initial symptoms [17,22]. The headache in our patient was thunderclap in nature. This is a severe type of headache that comes

in sudden attacks, reaching a peak within 1 min from the onset. This type of headache can be seen in various diseases particularly in subarachnoid hemorrhage. Although thunderclap headache is linked to the CVST, it was found that only a minority of CVST patients present with it. Most of the VrCVST cases developed acute headaches which is consistent with the presentation of CVST in general [24].

Our patient's lapse of consciousness and thumb movements are suggestive of focal seizure. In our literature search, 4 out of 13 patients developed seizures [15,18,22,23]. This is compatible with CVST due to other causes, in which 30-40% of patients develop acute symptomatic seizures which occur within 2 weeks of the diagnosis [25].

The CSF analysis of our patient showed an increase in RBC counts secondary to a traumatic lumbar puncture; the CSF was otherwise normal. CSF analysis was done in 8 out of the 13 reported VrCVST cases, 3 of which were completely normal. Of the other 5 cases, 3 had mild pleocytosis and a mild increase in protein [19,23]; among these, only 1 confirmed

the presence of the virus in the CSF by PCR. Two cases had a slight increase in protein in the CSF [16,20], with positive IgM in CSF in only 1 of them. These results indicate that VrcVST can occur as a complication of varicella, even without central nervous system (CNS) infection.

Most of the reported VrcVST cases excluded other causes of thrombophilia, which suggests that primary varicella can directly cause CVST. Protein S deficiency was reported in 3 of the 13 cases, of which 1 presented with protein C deficiency. Protein S and C deficiencies can be preexisting or induced by VZV infection [18,22]. VZV infection-induced protein S deficiency is reported in the literature to occur by inducing the

Table 2. Patients with cerebral venous sinus thrombosis complicating varicella zoster primary infection.

	Khan 2019 [15]	Mehta 2018 [16]	Imam 2017 [17]	Shrivastava 2016 [23]	Paul 2016 [18].2
Age	26	20	39	18	37
Sex	Male	Male	Male	Male	Male
CVST manifestations	– Seizures – Left side weakness	– Altered sensorium – Headache	– Headache – Vomiting	– Severe sudden onset headache – Vomiting – Seizures	– Seizure – Headache
Chicken pox onset	2 weeks prior to presentation	2 weeks prior to presentation	7 days prior to presentation	2 weeks prior to presentation	3 weeks prior to presentation
Neurological deficit	– Drowsiness – Hemiparesis Power 4/5	– Confusion – Aphasia	Non	Non	– Left side hemiparesis
Meningeal signs	No meningeal sign	Nuchal rigidity	Slight neck stiffness	Not mentioned	No meningeal signs
Fundoscopy	Not mentioned	Normal on the beginning then developed papilledema	Not mentioned	Bilateral papilledema	Not mentioned
Site	– Superior sagittal vein and left transverse sinus	Dural sinus thrombosis, involving left transverse, sigmoid sinuses, and internal jugular vein (IJV)	Extensive cerebral venous sinus thrombosis	Superior sagittal sinus, left transverse and sigmoid sinuses	Superior sagittal, right transverse and sigmoid sinus
CT or MRI Gray and white matter changes	Hemorrhage and Brain edema	MRV T2 fluid attenuated inversion recovery (FLAIR) hyperintense area in the left temporo-parieto-occipital area, suggestive of subacute infarct (left MCA and posterior cerebral artery territory) with effacement of cortical sulci seen on the left side, suggestive of edema	Not mentioned	CT: Hyper density in Superior sagittal sinus. MRV: Thrombosis of superior sagittal sinus, left transverse and sigmoid sinuses	Right frontoparietal venous infarction

APPROVED GALLEY PROOF

Table 2 continued. Patients with cerebral venous sinus thrombosis complicating varicella zoster primary infection.

	Khan 2019 [15]	Mehta 2018 [16]	Imam 2017 [17]	Shrivastava 2016 [23]	Paul 2016 [18].2
CSF analysis	Normal	CSF was clear and the opening pressure was normal. CSF report showed normal leukocyte count of 5 cells/mm ³ , all lymphocytes with mildly raised CSF protein (62.1 mg/dL) and with normal sugar (79 mg/dl). CSF IgM for VZV was positive	Not mentioned	Pleocytosis with 40 cells/mm ³ , mildly raised protein 60 mg% and normal glucose	Not mentioned
Serum (Ig M/G)	Positive IgM	Mentioned to be positive	Not mentioned	Not mentioned	Not mentioned
VZV IgG in CSF (CSF) and blood reduced serum/CSF ratios of VZV IgG	Not mentioned	Not mentioned	Not mentioned	Not mentioned	Not mentioned
Presence of other thrombosis sites	Pulmonary embolism	no	no	No	Right atrium thrombosis, Pulmonary embolism, left femoral and distal popliteal vein
Other Thrombophilia ruled out	No	Coagulation profile normal and homocysteine normal	No	Yes	Yes
Treatment	– Oral acyclovir – Oral apixaban then After PE enoxaparin 1 mg/kg twice daily until he improved, and was discharged on oral anticoagulation with apixaban – Anticonvulsant	– IV acyclovir – Low-molecular-weight heparin and Acitrom 2 mg OD – Ceftriaxone (2 g BD) – Mannitol 20% (100 ml TDS) – Corticosteroids (dexamethasone 8 mg TDS)	– Intravenous acyclovir – Heparin followed with Warfarin	– Antiviral before admission – Dabigatran – Antiedema measures	– Oral acyclovir – Unfractionated heparin followed with oral anticoagulation – Antiepileptics
Outcome	Improved	Complete recovery	Complete recovery.	Complete recovery	He gradually improved. and day 12 total recovery

APPROVED GALLEY PROOF

Table 2 continued. Patients with cerebral venous sinus thrombosis complicating varicella zoster primary infection.

	Paul 2016 [18].1	Gayathri 2016 [19]	Sardana 2014 [20]	Mathew 2013 [13]
Age	30	23	30	33
Sex	Male	Male	Male	Female
CVST manifestations	– Headache – Left side weakness	– Headache – Altered sensorium – Left side weakness	– Headache – Projectile vomiting – Rt side weakness	– Headache – Vomiting
Chicken pox onset	3 weeks prior to presentation	2 weeks prior to presentation	2 weeks prior to presentation	16 days prior to presentation.
Neurological deficit	– Drowsiness – Left-sided hemiparesis;	– Drowsiness and restless – Left eye abducent nerve palsy – Left hemiparesis with muscle power of 3/5	– Confusion – Wernicke’s aphasia – Right sided hemiparesis with power of 4/5 in right upper limb and 3/5 in right lower limb	None
Meningeal signs	Not mentioned	Nuchal rigidity (+ve Kernig sign)	Nuchal rigidity	Not mentioned
Fundoscopy	Bilateral papilledema	Bilateral papilledema.	Normal	Bilateral papilledema
Site	Transverse sinus and sigmoid sinus on the right side	Superior sagittal, bilateral transverse and right sigmoid sinuses which extends into the straight sinus	Left transverse and sigmoid sinus	Right transverse, sigmoid and straight sinuses
CT or MRI Gray and white matter changes	Hemorrhagic infarct in the right temporoparietal lobe with edema and mass effect	Venous hemorrhagic infarcts were seen in right frontoparietal cerebral parenchyma (largest 4 cm in length) and in right thalamus. Multiple lacunar infarcts in bilateral frontoparietal white matter	CT scan showed a hemorrhagic infarct in the left temporo-parietal lobe with edema and mass effect over the ipsilateral lateral ventricle. MRV with gadolinium hemorrhagic infarct with significant perilesional edema and adjacent meningeal enhancement in left tempo-parietal region with mass effect. Venography showed loss of normal signal intensity in transverse sinus and sigmoid sinus on left side	Magnetic resonance imaging and venography revealed thrombosis of right transverse, sigmoid, and straight sinuses without venous infarcts or hemorrhages
CSF analysis	Not mentioned	Pleocytosis with 20 cells/mm ³ , mildly raised protein 60 mg%, and normal glucose (40 mg%). CSF VZV DNA by PCR was positive	Cell counts: 3 cells/mm ³ ; protein 46 mg%, and glucose 54 mg%	Not mentioned
Serum (Ig M/G)	Not mentioned	Positive for IgG	Not mentioned.	Not mentioned
VZV IgG in CSF (CSF) and blood reduced serum/CSF ratios of VZV IgG	Not mentioned	Positive IgG with reduced serum/CSF ratios of VZV IgG	Positive IgG Reduced serum/CSF ratio of VZV IgG	Not mentioned

APPROVED GALLEY PROOF

Table 2 continued. Patients with cerebral venous sinus thrombosis complicating varicella zoster primary infection.

	Paul 2016 [18].1	Gayathri 2016 [19]	Sardana 2014 [20]	Mathew 2013 [13]
Presence of other thrombosis sites	No	No	No	No
Other thrombophilia ruled out	Low protein s	Yes	Yes	No
Treatment	– LMWH followed with oral anticoagulation – Antiedema measures	Iv heparin followed with oral anticoagulation	– V Acyclovir – Low molecular weight heparin for one week followed with Acitrom 2 mg orally – cerebral decongestants	– IV acyclovir – Subcut enoxaparin
Outcome	He gradually improved over 3 weeks.	Improved	Headache and language function gradually improved over few days. Hemiparesis gradually improved over 4 weeks	Complete recovery
	Menon 2012 [14]	Sada 2012 [21]	Siddiqi 2012 [22].2	Siddiqi 2012 [22].1
Age	20	30	15	20
Sex	Female	Male	Male	Male
CVST manifestations	– Severe headache – Irrelevant speech	– Headache – Nonprojectile vomiting	– Seizures	– Altered sensorium with progressive drowsiness – Seizure
Chicken pox onset	Unclear	15 days prior Presentation	3 weeks prior to presentation	1-week prior to presentation
Neurological deficit	– Fluent aphasia and phonemic paraphasia in both oral and written language – Right hemianopia – Minimal right hemiparesis	Non	– Disorientation – Right hemiparesis	– Disorientation – No motor deficits
Meningeal signs	Nuchal rigidity	Not mentioned.	Not mentioned.	No meningeal signs.
Fundoscopy	Normal	Bilateral papilledema.	Not mentioned	Normal
Site	– Transverse sinus, Sigmoid sinus and straight sinus on the left side	Superior sagittal and right transverse sinuses	Central venous sinus thrombosis	Central venous sinus thrombosis
CT or MRI Gray and white matter changes	Hemorrhagic infarct in the left temporal lobe with edema and mass effect over the ipsilateral lateral ventricle.	CT: brain showed diffuse cerebral edema and hyperdense superior sagittal and right transverse sinuses. MRV: showed thrombosis of superior sagittal and right transverse sinuses	MRI revealed extensive CVST MRA showed focal area of narrowing in the left distal middle cerebral artery just before trifurcation with a relative paucity of the left Sylvian branches, suggesting vasculitis	Widespread CVST

Table 2 continued. Patients with cerebral venous sinus thrombosis complicating varicella zoster primary infection.

	Menon 2012 [14]	Sada 2012 [21]	Siddiqi 2012 [22].2	Siddiqi 2012 [22].1
CSF analysis	Pleocytosis with 40 cells/mm ³ , mildly raised protein 60 mg%, and normal glucose	Not specifically mentioned	Normal	Normal
Serum (Ig M/G)	Not mentioned	Positive IgG	Not mentioned	Not mentioned
VZV IgG in CSF (CSF) and blood reduced serum/CSF ratios of VZV IgG	Not mentioned	Positive IgG with Reduced serum/CSF ratios of VZV IgG	Not mentioned	Not mentioned
Presence of other thrombosis sites	No	No	No	No
Other thrombophilia ruled out	Yes	yes	Yes	yes
Treatment	– Low molecular weight heparin followed with oral anticoagulation – intravenous 20% mannitol and dexamethasone	– IV acyclovir – Subcut enoxaparin followed with Acenocoumarin – Mannitol and dexamethasone	– IV heparin and oral anticoagulation	– IV acyclovir – Anticoagulation – Anticonvulsant
Outcome	Total recovery	Complete recovery	Complete recovery	Complete recovery

production of anti-protein S [26]. Furthermore, transient and persistent emergence of the antiphospholipid antibodies were also reported in a few patients with VZV to induce arterial and/or venous thrombosis [27,28]. Our patient had transient positive anticardiolipin and lupus anticoagulant, which could have caused the thrombosis. A recent systematic review of case reports found that particular infections can induce transient and persistent positive lupus anticoagulant and/or APS antibodies; many of these cases developed thrombosis [29]. However, the relationship between infection-induced transient positive APS antibodies and thrombosis needs further investigations to determine the significance and thus help determine strategies for prevention and treatment.

The pathogenesis of the thrombotic complications in VZV is unclear. However, it seems that different thrombotic manifestations are secondary to different etiologies and mechanistic pathways. Vasculopathic changes seem to be the main etiology for various manifestations, such as ischemic and hemorrhagic strokes, giant cell arteritis, external vasculopathy, and cranial neuropathies, among others, particularly in herpes zoster [30]. Two of the 11 VrCVST cases developed thrombosis in sites other than the CNS, which indicates a varicella-induced general prothrombotic status rather than CNS viral invasion-induced

thrombosis. The former can be due to the direct activation of the coagulation cascade by the VZV infection or due to varicella-induced APS or protein S/C deficiency [18,22,31]. Normal CSF chemistry and negative VZV PCR in most of the reported cases further support this notion. No tissue histology was obtained to confirm these assumptions. Other VZV-related thrombotic complications were attributed to vasculopathy due to direct infection of the blood vessels. This was confirmed by the presence of VZV DNA or its antibodies in the CSF in autopsy studies of patients who died of intracranial VZV-related vasculopathy [32]. It is important to note that most of the infection-related CVSTs were found to be due to local infections such as ears, sinuses, mouth, face, or neck rather than systemic infection, which might support the argument for viral invasion as a possible cause of VrCVST [9].

Furthermore, we found that all the reported VrCVT cases came from the Indian subcontinent, but it is unclear why this is so. However, we hypothesized possible explanations. First, it could be related to the low socioeconomic status and poor nutrition in the subcontinent. Second, it could be related to the unavailability of the vaccine in this population. Third, there might be genetic susceptibility of these patients to VZV, which makes them react to the virus differently, inducing vasculopathy and/

APPROVED GALLEY PROOF

or thrombosis. Fourth, the VZV genotype varies according to geographic distribution, and it could be that the VZV genotype that is prevalent in these countries is particularly pathogenic [33]. However, no data about the VZV genotype that infected these patients are available. Furthermore, our patient acquired the infection in Qatar, which is a part of the Middle East. All these hypotheses need further studies to establish correlations.

VrCVST usually has a favorable outcome. Most of the patients in the cases reported had improvement of their symptoms with no recurrence of seizure or thrombosis (Table 2). Most patients were treated with acyclovir, either IV or oral. For anticoagulation, heparin and vitamin K antagonist were mainly used. One patient was treated with apixaban, but he developed a pulmonary embolism and was thus switched to enoxaparin. One patient was treated successfully with dabigatran.

It is important to point out that the early recognition and the prompt treatment of CVST is crucial, as this was found to decrease the complications and significantly improve the outcomes [6]. Cerebral hernia caused by cerebral edema is the most common cause of death in patients with CVST. Although

there were no deaths among the reported VrCVST patients, it is crucial to recognize malignant CVST when patients exhibit progressive symptoms, as these patients should be monitored closely and decompressive surgery should be promptly considered [34].

Conclusions

This report shows that primary VSV infection can be associated with vasculopathy and cerebral venous sinus thrombosis. Early recognition of this complication of VZV infection and prompt treatment are essential to prevent catastrophic complications.

Acknowledgment

We thank Mr. Sa'ad Lews for his contribution in the literature review.

Conflict of Interest

None.

References:

1. Arvin AM. Varicella-zoster virus. *Clin Microbiol Rev.* 1996;9(3):361-81
2. Guess HA, Broughton DD, Melton LJ 3rd, Kurland LT. Chickenpox hospitalizations among residents of Olmsted County, Minnesota, 1962 through 1981. A population-based study. *Am J Dis Child.* 1984;138(11):1055-57
3. Preblud SR. Age-specific risks of varicella complications. *Pediatrics.* 1981;68(1):14-17
4. Gnann JW Jr. Varicella-zoster virus: Atypical presentations and unusual complications. *J Infect Dis.* 2002;186(Suppl.1): S91-S98
5. Ferro JM, Aguiar de Sousa D. Cerebral venous thrombosis: An update. *Curr Neurol Neurosci Rep.* 2019;19(10):74
6. Luo Y, Tian X, Wang X. Diagnosis and treatment of cerebral venous thrombosis: A review. *Front Aging Neurosci.* 2018;10:2
7. Coutinho JM, Ferro JM, Canhão P, et al. Cerebral venous and sinus thrombosis in women. *Stroke.* 2009;40(7):2356-61
8. Saposnik G, Barinagarrementeria F, Brown RD Jr, et al. Diagnosis and management of cerebral venous thrombosis: A statement for healthcare professionals from the American Heart Association/American Stroke Association. *Stroke.* 2011;42(4):1158-92
9. Duman T, Uluduz D, Midi I, et al. A multicenter study of 1144 patients with cerebral venous thrombosis: The VENOST study. *J Stroke Cerebrovasc Dis.* 2017;26(8):1848-57
10. Khealani BA, Wasay M, Saadah M, et al. Cerebral venous thrombosis: A descriptive multicenter study of patients in Pakistan and Middle East. *Stroke.* 2008;39(10):2707-11
11. Dentali F, Poli D, Scoditti U, et al. Long-term outcomes of patients with cerebral vein thrombosis: A multicenter study [published correction appears in *J Thromb Haemost.* 2013;11(2):399]. *J Thromb Haemost.* 2012;10(7):1297-302
12. Ruiz-Sandoval JL, Chiquete E, Bañuelos-Becerra LJ, et al. Cerebral venous thrombosis in a Mexican multicenter registry of acute cerebrovascular disease: The RENAMEVASC study. *J Stroke Cerebrovasc Dis.* 2012;21(5):395-400
13. Mathew T, Lobo A, Sarma GK, Nadig R. A case of post varicella cortical venous thrombosis successfully treated with dabigatran. *Neurology India.* 2013;61(5):531-32
14. Menon B, Goyal R. Cerebral venous thrombosis as a complication of chicken pox. *Ann Trop Med Public Heal.* 2012;5:520
15. Khan R, Yasmeen A, Pandey AK, et al: Cerebral venous thrombosis and acute pulmonary embolism following varicella infection. *Eur J Case Rep Intern Med.* 2019;6(10):001171
16. Mehta A, Arora A, Sharma M, et al: Hemorrhagic stroke and cerebral venous thrombosis: rare neurological sequelae of chickenpox infection. *Ann Indian Acad Neurol.* 2018;21(3):228-32
17. Imam SF, Lodhi OUH, Fatima Z, et al: A unique case of acute cerebral venous sinus thrombosis secondary to primary varicella zoster virus infection. *Cureus.* 2017;9(9):e1693
18. Paul G, Paul BS, Singh G. Unseen face of varicella-zoster infection in adults. *Indian J Crit Care Med.* 2016;20(12):731-34
19. Gayathri K, Ramalingam PK, Santhakumar R, et al. Cerebral sinus venous thrombosis as a rare complication of primary varicella zoster virus infection. *J Assoc Physicians India.* 2016;64(7):74-76
20. Sardana V, Mittal LC, Meena SR, et al. Acute venous sinus thrombosis after chickenpox infection. *J Assoc Physicians India.* 2014;62(8):741-43
21. Sada S, Kammineni A, Kanikannan MA, Afshan J. Cerebral sinus venous thrombosis: A rare complication of primary varicella zoster virus. *Neurol India.* 2012;60(6):645-46
22. Siddiqi SA, Nishat S, Kanwar D, et al. Cerebral venous sinus thrombosis: association with primary varicella zoster virus infection. *J Stroke Cerebrovasc Dis.* 2012;21(8):917.e1-4
23. Shrivastava K, Sundaresan N, Senthilkumar P. Cerebral venous thrombosis following varicella infection. *J Assoc Physicians India.* 2016;64(7):68-69
24. Sparaco M, Feleppa M, Bigal ME. Cerebral venous thrombosis and headache – a case-series. *Headache.* 2015;55(6):806-14
25. Silvis SM, de Sousa DA, Ferro JM, Coutinho JM. Cerebral venous thrombosis. *Nat Rev Neurol.* 2017;13(9):555-65
26. Peyvandi F, Faioni E, Alessandro Moroni G, et al. Autoimmune protein S deficiency and deep vein thrombosis after chickenpox. *Thromb Haemost.* 1996;75(1):212-13
27. Frontino G, Passoni A, Piscopo MA, et al. Bilateral cavo-ilio-femoral thrombosis in an adolescent with transient anti-phospholipid antibodies and factor V heterozygous mutation: A case report. *Cases J.* 2009;2:6830
28. Uthman IW, Gharavi AE. Viral infections and antiphospholipid antibodies. *Semin Arthritis Rheum.* 2002;31(4):256-63

29. Abdel-Wahab N, Lopez-Olivo MA, Pinto-Patarroyo GP, Suarez-Almazor ME. Systematic review of case reports of antiphospholipid syndrome following infection. *Lupus*. 2016;25(14):1520-31
30. Nagel MA, Gildea D. Update on varicella zoster virus vasculopathy. *Curr Infect Dis Rep*. 2014;16(6):407
31. Mandel EE. Hypercoagulability. *Chic Med*. 1961;63:19-24
32. Gildea DH, Kleinschmidt-DeMasters BK, Wellish M, et al. Varicella zoster virus, a cause of waxing and waning vasculitis: The New England Journal of Medicine case 5 – 1995 revisited. *Neurology*. 1996;47(6):1441-46
33. Hosogai M, Nakatani Y, Mimura K, et al. Genetic analysis of varicella-zoster virus in the aqueous humor in uveitis with severe hyphema. *BMC Infect Dis*, 2017;17:427
34. Théaudin M, Crassard I, Bresson D, et al. Should decompressive surgery be performed in malignant cerebral venous thrombosis? A series of 12 patients. *Stroke*. 2010;41(4):727-31