

Received: 2020.09.23

Accepted: 2020.12.27

Available online: 2021.02.11

Published: 2021.XX.XX

Low-Concentration (0.66%) Povidone Iodine Treatment of a Corneal Ulcer in a Rheumatoid Arthritis Patient

E Paolo Bordin

Department of Ophthalmology, ULSS9 Scaligera, Legnago Hospital, Verona, Italy

Authors' Contribution:

Study Design A

Data Collection B

Statistical Analysis C

Data Interpretation D

Manuscript Preparation E

Literature Search F

Funds Collection G

Corresponding Author: Paolo Bordin, e-mail: paolobordin@aulss9.veneto.it
Conflict of interest: None declared

Patient: Female, 89-year-old
Final Diagnosis: Corneal ulcer
Symptoms: Low vision
Medication: —
Clinical Procedure: —
Specialty: Ophthalmology

Objective: Unusual clinical course
Background:

Peripheral ulcerative keratitis is one of the ocular complications associated with chronic inflammatory immune-mediated diseases, such as rheumatoid arthritis, in which inflammatory reactions and infections can be recurrent.

Suspected infections are treated with topical antibiotics that, in some cases, may promote selection of resistant microbes. Povidone iodine is known for its rapid broad-spectrum activity against all kinds of microbes and biofilms, lack of microbial resistance, ability to counteract excessive inflammation, and efficacy in wound healing, along with an optimum safety and tolerability profile.

The purpose of this case report is to show the resolution of a peripheral ulcerative keratitis case by means of treatment with 0.66% povidone iodine.

Case Report: An 89-year-old woman with rheumatoid arthritis, 1 eye, and a superior descemetic corneal ulcer was treated with amniotic membrane, topical antibiotics, and antiviral drugs without any control of clinical signs and symptoms. Therefore, all anti-infective treatments were replaced with 0.66% povidone iodine (3 times/day) given alone for 5 weeks and then associated with serum eyedrops. When a clear regression of the ulcer was observed, the patient was maintained with serum eyedrops only.

Conclusions: Unusual treatment with povidone iodine 0.66% (used for the first time in an autoimmune patient), alone and in association with serum eyedrops, probably contributed to alleviate the signs and symptoms of a case of peripheral ulcerative keratitis not responding to conventional treatments. Although its regular use warrants further investigation, povidone iodine seems a useful therapeutic tool for the treatment of corneal ulcers associated with chronic immune-mediated inflammatory diseases.

Keywords: Arthritis, Rheumatoid • Corneal Ulcer • Povidone-Iodine

Full-text PDF: <https://www.amjcaserep.com/abstract/index/idArt/928748>

 2220 — 5 47

Background

Rheumatoid arthritis (RA) is frequently associated with sight-threatening ocular manifestations such as corneal and scleral disorders [1-3]. This autoimmune and chronic inflammatory systemic disease, in fact, involves extra-articular complications that include ophthalmological manifestations, sometimes representing the first signs of the pathology. RA is often linked to episcleritis, scleritis, keratoconjunctivitis sicca, peripheral ulcerative keratitis (PUK), anterior uveitis, and retinal vasculitis [4,5]. Any component of the eye can be affected in RA, as the damage of the ocular tissues is autoimmune mediated [6].

Medical therapy of RA involves systemic administration of drugs able to suppress the immune system and the inflammatory processes. Topical therapy to treat or prevent ophthalmologic complications of the disease includes immunosuppressants (such as cyclosporin and tacrolimus), corticosteroids to suppress inflammation [6], and antibiotics when an infective component is suspected [7]. Some selected cases may require amniotic membrane implantation [8].

Subjects with chronic inflammatory autoimmune disorders, such as RA patients, are more susceptible to infections than healthy subjects [9]. RA is often linked to 2-fold increased risk of infections and 4-fold increased risk of dose dependence related to the long-term use of glucocorticoids, which are potent immunosuppressive drugs [10,11]. The increased susceptibility of these patients can be explained by the pathobiology of the disease itself, the impact of eventual chronic comorbidity, or sequelae of immunosuppressive treatment. The mechanism hypothesized for that is the premature aging of the immune system, which can contribute to deficient protection against infectious organisms [12]. Among other ocular complications associated with inflammatory rheumatic diseases, corneal ulcer, is not a frequent complication but is dangerous for the eye as it can lead to perforation. The pathophysiology of the corneal melting is primarily linked to immune-mediated reactions and unstable epithelial barrier [3]. Medical management of PUK is necessary to reduce the underlying inflammatory or infectious causes, although sometimes surgical intervention with a nonperforating corneal graft is required [13].

In clinical practice, suspected ocular infections are empirically treated with topical antibiotics that (in most cases) are usually given without pre-identification of the pathogen, at sub-therapeutic dosage and, often, for inadequate duration [14]. Moreover, microbiological examination of ophthalmic samples often takes a long time and may not be reliable because of the lack of material recovered. This clinical management often leads to the choice of incorrect and ineffective therapies responsible for worsening the ocular pathology. Therefore, antibiotics are often misused and overused in the treatment of

ocular surface infections [15]. Inappropriate use of antibiotics has led to an increase in cases of antibiotic resistance, which is becoming one of the major health-care challenges of this century [16]. This may promote a qualitative-quantitative selection of resistant microbial strains that can only worsen the clinical condition. Since corneal ulcers are frequently caused by a multitude of pathogens [17], the use of topical antibiotics should be discouraged because of increasing resistance, and the choice of an antiseptic agent [18] could be more appropriate.

An existing alternative in ophthalmology is the use of antiseptics, as they have a nonselective mechanism of action capable of preventing the development of resistance [19]. Povidone iodine (PVI) is the criterion standard antiseptic in ophthalmology. It is known for its rapid broad-spectrum activity against bacteria, bacterial spores, fungi, viruses, and protozoa [20]. It is also active against *Acanthamoeba* [21] and biofilms that are known to delay wound healing and promote bacterial survival during antimicrobial treatments [21,22]. PVI is also particularly indicated for wound healing because of its effect on excessive inflammation [23,24]. Furthermore, it can prevent resistant bacterial strain selection or cross-resistance caused by antibiotics [25]. There are no reports concerning anaphylaxis or resistance in topical ophthalmic use of PVI [25].

This report describes the resolution of a corneal ulcer in a 1-eyed RA patient at high risk of corneal transplantation treated for the first time with a formulation containing 0.66% aqueous PVI. The purpose of the case report is to show that the substitution of conventional antimicrobial treatments with a specific formulation, characterized by low-concentration PVI (0.66%), hyaluronic acid, glycerol, and medium-chain triglycerides, has substantially contributed to resolve the ulcer.

Case Report

The patient signed informed consent to authorize the publication of this case report.

An 89-year-old woman with RA diagnosed in 2010, treated with corticosteroids until 2018, with 1 eye (enucleated due to glaucoma), a nonsmoker, with glaucoma in the left eye, undergoing topical therapy with dorzolamide-timolol, had already visited another clinic for severe pain in the left eye in September 2018. The ophthalmic visit highlighted a deep corneal ulcer located in the upper sector of the cornea. A conjunctival swab was taken and corneal grattage was performed to search for pathogens, but both results were negative and it was not possible to identify the etiology of the ulcer. Therapy with topical antibiotics (aminoglycosides and quinolones) and with topical and systemic antiviral (acyclovir) was performed but did not affect the evolution of the ocular lesion, which progressed

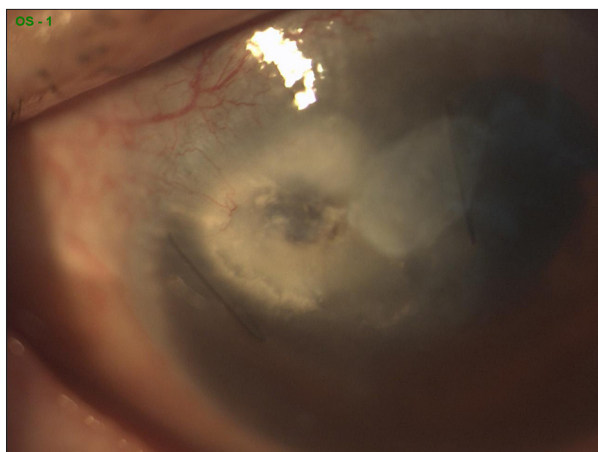


Figure 1. First visit. Descemetocele, 2 corneal nylon 10-0 sutures, and amniotic membrane trace.

up to descemetocele. Herpes simplex virus-related corneal ulcer was diagnosed.

In March 2018, the patient underwent curettage of the ulcer edge and the amniotic membrane was implanted. Topical therapy included topical antibiotics (netilmicin, chloramphenicol), corticosteroids (dexamethasone, fluorometholone), antihypertensive (travoprost), and artificial tears for 1 month, whereas systemic therapy included acetazolamide and the antiviral (acyclovir). Despite the graft and the multiple treatments, descemetocele and marginal corneal ulcer were still present.

The next year (in May 2019), the patient came to our clinic reporting persistent pain and photophobia (started in September 2018) that were causing considerable reduction of quality of life. She referred a 1/10 visus. Ophthalmic examination confirmed pre-descemetic corneal ulcer (Figure 1), 2 nylon stitches due to previous application of amniotic membrane, hypertonic bulb, therapeutic contact lens, and visus not evaluable. No optical coherence tomography (OCT) images of the cornea were produced because the patient had severe horizontal nystagmus and the OCT was not executable. Both nylon stitches and contact lens were removed and it was decided to replace the antimicrobial current therapy with a solution containing 0.66% PVI, hyaluronic acid, glycerol, and medium-chain triglycerides (IODIM®, Medivis S.r.l.), administered 4 times a day. Intraocular hypertension was still treated with dorzolamide and timolol (twice a day) and oral administration of acetazolamide 250 mg ($\frac{1}{2}+\frac{1}{2}$ capsule/day) was also added.

The patient visited our clinic 3 times during the follow-up and each time she reported an improvement in the symptomatology from the very start of the new therapy.

After 5 weeks (June 28) from the beginning of the therapy with IODIM, a clear regression of the corneal ulcer was observed

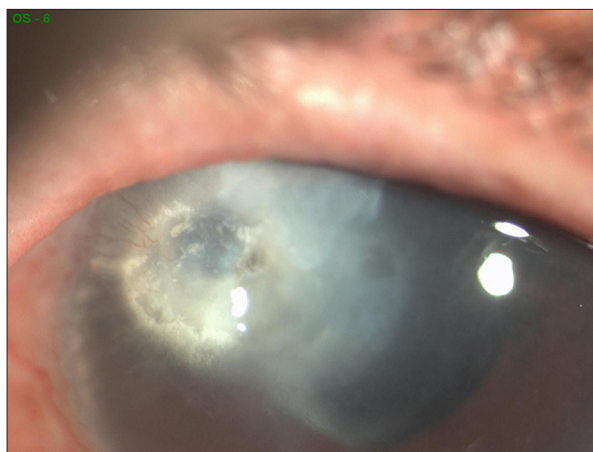


Figure 2. Regression of corneal ulcer after 5 weeks of 0.66% PVI, hyaluronic acid, glycerol, and medium-chain triglycerides (IODIM®, Medivis S.r.l.) treatment (4 times/day).

(Figure 2) even in absence of OCT images, as it has been possible to follow the variation of the step at the edge of the ulcer. The amelioration of the ulcer was concomitant with the improvement of the patient's symptomatology, reduction of pain, and photophobia. The bulb was normotonic but the visus was still not evaluable. The patient declared that she had been able to return to her normal daily activities.

Therapy was slightly modified by reducing acetazolamide ($\frac{1}{2}$ capsule/day) and IODIM to 3 times/day (instead of 4) and undiluted autologous serum eyedrops 4 times/day were added.

The month after the last visit, a significant improvement of the corneal ulcer with a visible decrease in wound depth was observed (Figure 3). Acetazolamide therapy was stopped.

A short time later, complete disappearance of the corneal ulcer was observed and no symptomatology was reported. For the first time, a 1/10 visus was registered and normal daily activities were further improved. Intraocular pressure was 18 mmHg. Antihypertensive therapy with dorzolamide and timolol and treatment with autologous serum eyedrops were maintained. IODIM was further reduced (twice a day) and stopped after 1 month.

After 3 months from the first visit, the patient was again evaluated and the complete resolution of the corneal ulcer was confirmed (Figure 4). It was decided to reduce the treatment with autologous serum eyedrops (3 times a day). This dose was stopped after 2 months when all clinical evaluations were confirmed.

The follow-up of the patient showed a stable condition of the cornea at each successive visit until almost 1 year after the

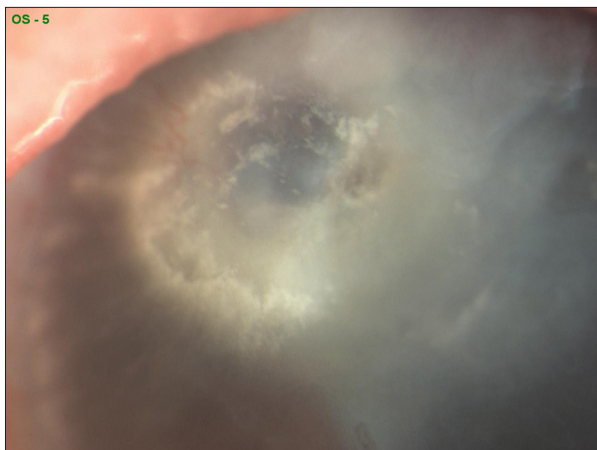


Figure 3. Improvement of corneal ulcer with letup of wound depth of corneal ulcer due to healing process after continuing 0.66% PVI, hyaluronic acid, glycerol, and medium-chain triglycerides (IODIM®, Medivis S.r.l.) treatment (3 times/day) and adding autologous serum eyedrops (4 times/day).

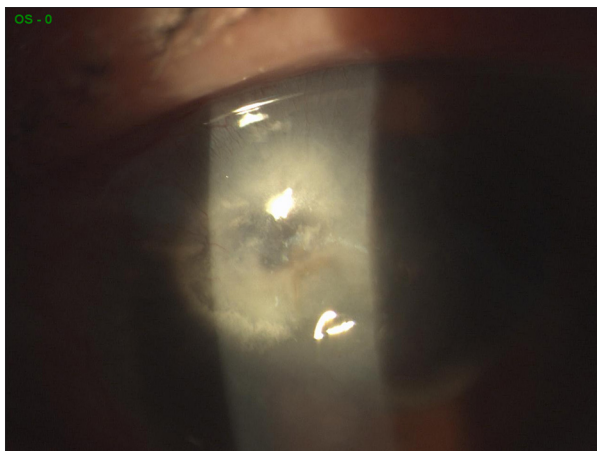


Figure 4. Three months after the first visit. Corneal ulcer closure confirmed after 5 weeks of 0.66% PVI, hyaluronic acid, glycerol, and medium-chain triglycerides (IODIM®, Medivis S.r.l.) therapy (2 times/day) and autologous serum eyedrops (4 times/day).

first visit (**Figure 5**), with no relapses during this period. The last follow-up in August 2020 confirmed a stable cornea at rest.

Discussion

A 5% aqueous PVI antiseptic solution is widely used in ophthalmology and is recommended by the European Society of Cataract and Refractive Surgeons guidelines in preparation for ophthalmic surgery [26]. However, 5% PVI is not well tolerated because of the very acidic pH, and it is toxic to the ocular surface [27]. The poor local tolerability of 5% iodine formulations

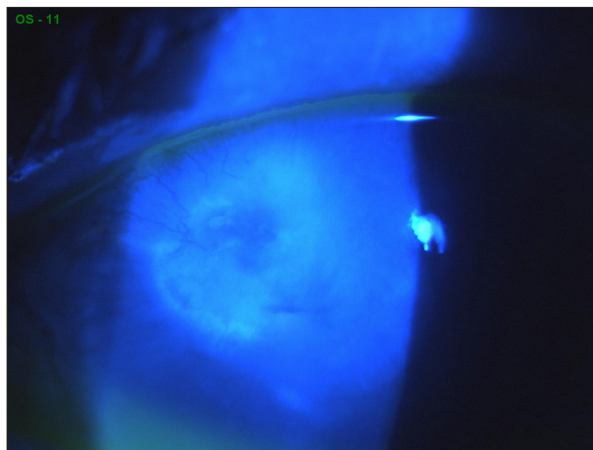


Figure 5. One year after the first visit. Intact corneal surface, stable healing.

suggests use of a lower concentration of PVI with a higher pH. Diluted PVI solutions will guarantee not only better tolerability, but also significantly greater and quicker antimicrobial activity than 5% concentrations [28]. This paradoxical effect of dilution is justified by the fact that more diluted solutions of PVI are able to release relatively greater quantities of free iodine [29].

In particular, the antimicrobial efficacy of ophthalmic aqueous solution containing 0.66% PVI was proven in 2 in vitro studies showing faster bactericidal activity compared with traditional 5% PVI solution [30,31]. This report describes for the first time the successful treatment of a case of PUK associated with chronic RA with the use of a 0.66% PVI aqueous solution containing hyaluronic acid, glycerol, and medium-chain triglycerides as vehicle. It is well known that among the different antimicrobial agents, formulations containing PVI have been widely used for antisepsis at concentrations ranging from 0.6% to 2.5% [32-35].

In addition to its broad spectrum of antimicrobial activity, lack of resistance, and efficacy against biofilms, an interesting aspect of PVI activity is its effectiveness in the wound-healing process thanks to its ability to reduce excessive inflammation induced by pathogens [36-40].

The optimum efficacy and tolerability profile of the PVI is also important [36]. PVI has been used and evaluated in wound healing for several years [36,41]. A recent review comparing PVI with other antiseptics such as chlorhexidine gluconate, polyhexanide, and octenidine concluded that, among them, PVI remains the ideal agent for the management of antisepsis in wound care as it can also promote wound healing through increased expression of transforming growth factor beta, neovascularization, and re-epithelialization [42,43]. This specific property could be particularly useful in the treatment of corneal ulcers associated with chronic immune-mediated

inflammatory diseases (such as RA) in which inflammation and infections could be recurrent.

Patients affected by autoimmune diseases may develop tear film alterations and dry eye with concomitant reduction of adequate lubrication of the corneal surface [44]. In this condition, the integrity of the corneal epithelium may fail, with the consequent formation of peripheral “sterile” corneal ulcers. In fact, the collagenopathy of autoimmune forms can be more susceptible to pathogens normally present on the ocular surface, generating a colliquation of the stromal tissue with consequent corneal perforation [45,46]. In this case, too, PVI could be supposed as the preferred treatment to prevent infections because of its safety profile at low concentration, and thanks to its multiple mechanisms of action [36]. The tolerability of the formulation used in the present report has been evaluated in a long-term treatment (4 weeks) of the ocular surface of patients with qualitative-quantitative alteration of the tear film and lacrimal dysfunction. The study demonstrated that after a 4-week treatment of 2 drops twice a day in dry eye subjects, the PVI formulation was well tolerated and also efficacious in improving symptoms and reducing the extent of injury of the ocular surface as shown by the increase in breakup time of the tear film and the reduction of epithelial distress highlighted with fluorescein staining [47]

The presence in the PVI formulation of hyaluronic acid, glycerol, and medium-chain triglycerides may have contributed to the improvement of the ocular surface health; in fact, the interaction of triglycerides with the lipid layer of the ocular surface reduces the evaporation of tears, whereas glycerol (hygroscopic) and the hyaluronic acid (water retention effect) may improve the aqueous layer of the tear film. Moreover, these

References:

1. Clavel G, Gabison E, Semerano L. Corneal and scleral involvement in inflammatory rheumatic disease: Rheumatologists and ophthalmologists exchanging views. *Joint Bone Spine*. 2019;86(6):699-705
2. Murray PI, Rauz S. The eye and inflammatory rheumatic diseases: The eye and rheumatoid arthritis, ankylosing spondylitis, psoriatic arthritis. *Best Pract Res Clin Rheumatol*. 2016;30(5):802-25
3. Hick S, Duchesne B, Kaye O, et al. Corneal ulcers associated with rheumatoid arthritis. *Rev Med Liege*. 2002;57(4):228-32
4. Artifoni M, Rothschild PR, Brézin A, et al. Ocular inflammatory diseases associated with rheumatoid arthritis. *Nat Rev Rheumatol*. 2014;10(2):108-16
5. Bhamra MS, Gondal I, Amarnani A, et al. Ocular manifestations of rheumatoid arthritis: Implications of recent clinical trials. *Int J Clin Res Trials*. 2019;4(2):139
6. Tong L, Thumboo J, Tan YK, et al. The eye: A window of opportunity in rheumatoid arthritis? *Nat Rev Rheumatol*. 2014;10(9):552-60
7. Yagci A. Update on peripheral ulcerative keratitis. *Clin Ophthalmol*. 2012;6:747-54
8. Jia Y, Gao H, Li S, et al. Combined anterior chamber washout, amniotic membrane transplantation, and topical use of corticosteroids for severe peripheral ulcerative keratitis. *Cornea*. 2014;33(6):559-64
9. Atzeni F, Bendtzen K, Bobbio-Pallavicini F, et al. Infections and treatment of patients with rheumatic diseases. *Clin Exp Rheumatol*. 2008;26(1 Suppl.48):S67-73
10. Bernatsky S, Hudson M, Suissa S. Anti-rheumatic drug use and risk of serious infections in rheumatoid arthritis. *Rheumatology (Oxford)*. 2007;46(7):1157-60
11. Ruiz-Irastorza G, Danza A, Khamashta M. Glucocorticoid use and abuse in SLE. *Rheumatology (Oxford)*. 2012;51(7):1145-53
12. Listing J, Gerhold K, Zink A. The risk of infections associated with rheumatoid arthritis, with its comorbidity and treatment. *Rheumatology (Oxford)*. 2013;52(1):53-61
13. Lohchab M, Prakash G, Arora T, et al. Surgical management of peripheral corneal thinning disorders. *Surv Ophthalmol*. 2019;64(1):67-78
14. Grzybowski A, Brona P, Kim SJ. Microbial flora and resistance in ophthalmology: A review. *Graefes Arch Clin Exp Ophthalmol*. 2017;255(5):851-62
15. Parke DW, Coleman AL, Rich WR, et al. Choosing wisely: Five ideas that physicians and patients can discuss. *Ophthalmology*. 2013;120(3):443-44
16. Ghosh D, Veeraraghavan B, Elangovan R, et al. Antibiotic resistance and epigenetics: More to it than meets the eye. *Antimicrob Agents Chemother*. 2020;64(2):e02225-19
17. Farahani M, Patel R, Dwarakanathan S. Infectious corneal ulcers. *Dis Mon*. 2017;63(2):33-37

substances can protect the corneal surface from the processes leading to perforation, helping to prevent the corneal epithelial lesions and, along with PVI, the eventual pathogen selection. The efficient antiseptic effect of PVI along with its optimum safety profile in the above-mentioned 0.66% PVI formulation may have contributed to the protection of the cornea and may have favored the healing process of the ulcer described in the present report. In other words, IODIM administration, thanks to its broad antiseptic activity along with its viscoelastic aqueous formulation, may have contributed significantly to the resolution of the ulcer in a patient previously treated with several conventional antimicrobial agents (antibiotics, antiviral, antifungals) that had no impact on the ocular lesion. If PVI can be demonstrated to be effective in large-scale clinical evaluations to treat ulcer cases in patients with autoimmune diseases, who are more susceptible to infection, there may be less indiscriminate use of antibiotics.

Conclusions

Low-concentration PVI, because of its broad antimicrobial properties, lack of resistance, rapidity of action, and efficacy against biofilms and excessive inflammation, and because of its favorable risk/benefit profile, especially in the wound-healing process, could be an additional treatment option for corneal ulcers associated with chronic immune-mediated inflammatory diseases or for other clinical cases with uncertain infective diagnosis.

Acknowledgments

The author thanks Dr Nicola Dalla Pellegrina of the Ophthalmic Surgery Department, Legnago Hospital.

18. European Wound Management Association (EWMA). Position Document: Management of Wound Infection, London, 2006
19. Grzybowski A, Turczynowska M. More antiseptics, less antibiotics whenever possible. *Asia Pac J Ophthalmol (Phila)*. 2018;7(2):72-75
20. Lachapelle JM, Castel O, Casado AF, et al. Antiseptics in the area of bacterial resistance a focus on povidone iodine. *Clin Pract*. 2013;10(5):579-92
21. Grzybowski A, Brona P. Povidone-iodine is still a premium antiseptic measure in ocular surgery. *Acta Ophthalmol*. 2017;95(3):e253-54
22. Phillips PL, Wolcott RD, Fletcher J, et al. Biofilms made easy. *Wounds Int*. 2010;1(3)
23. Bigliardi PL. Povidone iodine in wound healing: A review of current concepts and practices. *Int J Surg*. 2017;44:260-68
24. Percival SL, Finnegan S, Donelli G, et al. Antiseptics for treating infected wounds: Efficacy on biofilms and effect of pH. *Crit Rev Microbiol*. 2016;42(2):293-309
25. Grzybowski A, Kancler P, Myers WG. The use of povidone-iodine in ophthalmology. *Curr Opin Ophthalmol*. 2018;29(1):19-32
26. Barry P, Cordovès L, Gardner S. ESCRS guidelines for prevention and treatment of endophthalmitis following cataract surgery: Data dilemmas and conclusion. European Society of Cataract and Refractive Surgeons, Dublin, Ireland, 2013, <http://www.es CRS.org/downloads/Endophthalmitis-Guidelines.pdf>
27. Jiang J, Wu M, Shen T. The toxic effect of different concentrations of povidone iodine on the rabbit's cornea. *Cutan Ocul Toxicol*. 2009;28(3):119-24
28. Berkelman RL, Holland BW, Anderson RL. Increased bactericidal activity of dilute preparations of povidone-iodine solutions. *J Clin Microbiol*. 1982;15:635-39
29. Rackur H. New aspects of mechanism of action of povidone-iodine. *J Hosp Infect*. 1985;6(Suppl.1): 13-23
30. Musumeci R, Bandello F, Martinelli M, et al. In vitro bactericidal activity of 0.6% povidone-iodine eye drops formulation. *Eur J Ophthalmol*. 2019;29(6):673-77
31. Pinna A, Donadu MG, Usai D, et al. In vitro antimicrobial activity of a new ophthalmic solution containing povidone-iodine 0.6% (IODIM®). *Acta Ophthalmol*. 2020;98(2):e178-80
32. Hale LM. The treatment of corneal ulcer with povidone-iodine (Betadine). *N C Med J*. 1969;30(2):54-56
33. Isenberg SJ, Apt L, Valenton M, et al. Prospective, randomized clinical trial of povidone-iodine 1.25% solution versus topical antibiotics for treatment of bacterial keratitis. *Am J Ophthalmol*. 2017;176:244-53
34. Koerner JC, George MJ, Kissam EA, et al. Povidone-iodine concentration and in vitro killing time of bacterial corneal ulcer isolates. *Digit J Ophthalmol*. 2018;24(4):24-26
35. Bordin P. Corneal ulcer treated with 0.66% nanoemulsion povidone-iodine: A case report. *Am J Case Rep*. 2020;21:e919822
36. Bigliardi PL, Latiff Alsagoff SA, El-Kafrawi HY, et al. Povidone iodine in wound healing: A review of current concepts and practices. *Int J Surg*. 2017;44:260-68
37. Beukelman CJ, van den Berg AJ, Hoekstra MJ, et al. Anti-inflammatory properties of a liposomal hydrogel with povidone-iodine (Repithel) for wound healing in vitro. *Burns*. 2008;34(6):845-55
38. Leaper DJ, Durani P. Topical antimicrobial therapy of chronic wounds healing by secondary intention using iodine products. *Int. Wound J*. 2008;5(2):361-68
39. Al-Kaisy AA, Salih Sahib A. Role of the antioxidant effect of vitamin E with vitamin C and topical povidone-iodine ointment in the treatment of burns. *Ann Burns Fire Disasters*. 2005;18(1):19-30
40. Eming SA, Smola-Hess S, Kurschat P, et al. A novel property of povidone-iodine: Inhibition of excessive protease levels in chronic non-healing wounds. *J Invest Dermatol*. 2006;126(12):2731-33
41. Ripa S, Bruno R, Reder R. Clinical applications of Povidone-Iodine as a topical antimicrobial. *Handbook of Topical Antimicrobials Industrial Applications, Industrial Applications in Consumer Products and Pharmaceuticals*. CRC Press, Boca Raton, Florida, 2002
42. Barreto R, Barrois B, Lambert J, et al. Addressing the challenges in antiseptics: Focus on povidone iodine. *Int J Antimicrob Agents*. 2020;56(3):106064
43. Wang L, Qin W, Zhou Y, et al. Transforming growth factor beta plays an important role in enhancing wound healing by topical application of povidone-iodine. *Sci Rep*. 2017;7(1):991
44. Stern ME, Schaumburg CS, Pflugfelder SC. Dry eye as a mucosal autoimmune disease. *Int Rev Immunol*. 2013;32(1):19-41
45. Deswal J, Arya SK, Raj A, et al. A case of bilateral corneal perforation in a patient with severe dry eye. *J Clin Diagn Res*. 2017;11(4):ND01-2
46. Petroustos G, Paschides CA, Kitsos G, et al. Sterile corneal ulcers in dry eye. Incidence and factors of occurrence. *J Fr Ophtalmol*. 1992;15(2):103-5
47. Oliverio GW, Spinella R, Postorino EI, et al. Safety and tolerability of an eye drop based on 0.6% povidone-iodine nanoemulsion in dry-eye patients. *J Ocul Pharmacol Ther*, 2020 [Online ahead of print]