

Received: 2020.10.28

Accepted: 2021.01.10

Available online: 2021.02.11

Published: 2021.XX.XX

# A 34-Year-Old Woman with a Diamniotic Dichorionic Twin Pregnancy Presenting with an Erythematous and Papular Skin Rash Associated with SARS-CoV-2 Infection

Authors' Contribution:  
Study Design A  
Data Collection B  
Statistical Analysis C  
Data Interpretation D  
Manuscript Preparation E  
Literature Search F  
Funds Collection G

ABD 1 **Liliana Oropeza Chávez**  
ABCDEF 2 **Ángel Sánchez Tinajero**  
ABCDF 2 **José Arturo Martínez Orozco**  
ABCD 3 **Eduardo Becerril Vargas**  
B 1 **Alfredo Dolores De la Merced**  
ABCDE 4 **Danna Patricia Ruiz Santillán**  
ABC 2 **Andrea Iraís Delgado Cueva**  
ABC 2 **Nestor Alvarado Peña**

1 Department of Reproductive Biology, UMARE Reproduction Clinic, Mexico City, Mexico  
2 Department of Infectious Diseases, National Institute of Respiratory Diseases (INER), Mexico City, Mexico  
3 Department of Laboratory of Clinical Microbiology, National Institute of Respiratory Diseases (INER), Mexico City, Mexico  
4 National School of Biological Sciences (ENCB), National Polytechnic Institute (IPN), Mexico City, Mexico

**Corresponding Author:** Ángel Sánchez Tinajero, e-mail: [angelsan111@gmail.com](mailto:angelsan111@gmail.com)

**Conflict of interest:** None declared

**Patient:** Female, 34-year-old  
**Final Diagnosis:** COVID-19 • Pregnancy  
**Symptoms:** Earache • fatigue •odynophagia  
**Medication:** —  
**Clinical Procedure:** Cesarean  
**Specialty:** Infectious Diseases • Microbiology and Virology • Obstetrics and Gynecology

**Objective:** Rare co-existence of disease or pathology





**Background:** The damage caused by the severe acute respiratory syndrome-coronavirus 2 (SARS-CoV-2) has been extensive. Pregnant women are a group requiring special attention in medicine given the anatomical and physiological changes that occur during pregnancy. Skin rash is commonly associated with pregnancy, with the most common form of an erythematous maculopapular rash being pruritic urticarial papules and plaques of pregnancy. Skin rash is also an increasingly reported initial presentation in patients with coronavirus disease 2019 (COVID-19), due to infection with SARS-CoV-2.

**Case Report:** A 34-year-old woman with a diamniotic dichorionic twin pregnancy presented with clinical picture characterized by dermatological manifestations, namely an erythematous and papular skin rash associated with SARS-CoV-2 infection. A real-time reverse transcription-polymerase chain reaction (GeneFinder) test was positive for SARS-CoV-2 detection.

**Conclusions:** Ten months after the onset of this pandemic, there is no conclusive evidence indicating that pregnant women represent a sector more or less vulnerable to severe forms of COVID-19 than the general population. This report has highlighted the importance of performing a reliable diagnostic test for SARS-CoV-2 infection in patients who present with a skin rash, particularly pregnant women.

**Keywords:** COVID-19 • Insemination, Artificial • Pregnancy Complications

**Full-text PDF:** <https://www.amjcaserep.com/abstract/index/idArt/929489>

 2051  —  2  22



## Background

Ten months after the onset of this pandemic, the severe acute respiratory syndrome coronavirus 2 (SARS-CoV-2) has claimed the lives of just over 2 million people globally [1]. Pregnant women are a group requiring special attention in medicine given the anatomical and physiological changes that occur during pregnancy. These changes also modify the susceptibility to the acquisition and management of infections, such as viral pneumonia. Pregnant women who have acquired respiratory infections such as Middle Eastern respiratory syndrome, severe acute respiratory syndrome, and influenza have developed more severe clinical presentations than non-pregnant women [2,3]. However, in this new pandemic, there is no conclusive evidence about whether this population is more or less susceptible to infection by this viral agent.

Since the beginning of the pandemic, it has been hypothesized that pregnant women will be more vulnerable to a severe form of SARS-CoV-2 pneumonia. This has been proposed by several physicians and scientists who, from analyzing the forms of clinical presentation and considering the similarities of genome and structural constitution of this new virus with other members of the *Coronaviridae* family, have suggested the need for paying more attention to pregnant women because of this potential risk. This suggestion is supported by the fact that, molecularly, there is a greater expression of the angiotensin 2 receptor (peremptory receptor for the entry of the virus into the cell) during pregnancy [4,5]. However, almost a year after this pandemic began, and despite the large amount of medical attention focused on this population, there is no clear scientific evidence supporting this theory.

In June 2020, Dashraath et al analyzed the results of 55 pregnant women with COVID-19. Although they did not find an increase in the susceptibility and severity of the SARS-CoV-2 infection compared with other infectious diseases, they found that the physiological changes in pregnancy, such as the disposition of the immune system toward a T helper 2 cell profile, can prevent the vertical transmission of the virus to a certain extent. Clinically, the gravid state can confuse and delay the timely diagnosis of COVID-19 owing to relatively frequent symptoms in pregnancy, such as gestational rhinitis and physiological dyspnea [6].

Skin rash is commonly associated with pregnancy, with the most common form of an erythematous maculopapular rash being pruritic urticarial papules and plaques of pregnancy [7-9]. However, skin rash is an increasingly reported initial presentation in patients with SARS-CoV-2 infection. This is the report of a 34-year-old woman with a diamniotic dichorionic twin pregnancy who presented with an erythematous and papular skin rash associated with SARS-CoV-2 infection.

## Case Report

A 34-year-old woman presented to our institution with a medical history of uterine fibroids (60×48 mm) and no other significant pathological history. Given the patient's age, previous anovulation diagnosis, absence of a partner, and her desire to become pregnant, she underwent gynecological evaluation. Considering the above, a low-complexity assisted reproduction technique was chosen, namely ovulation induction with intrauterine insemination (sperm supplied by a sperm bank). The patient achieved a dichorionic diamniotic twin pregnancy, which was confirmed in the first trimester. Ultrasonographic patterns, such as nuchal translucency, and the patient's maternal age were assessed to calculate a baseline and the adjusted risk for trisomies 21, 18, and 13. Both twins showed a low risk for all 3 of them.

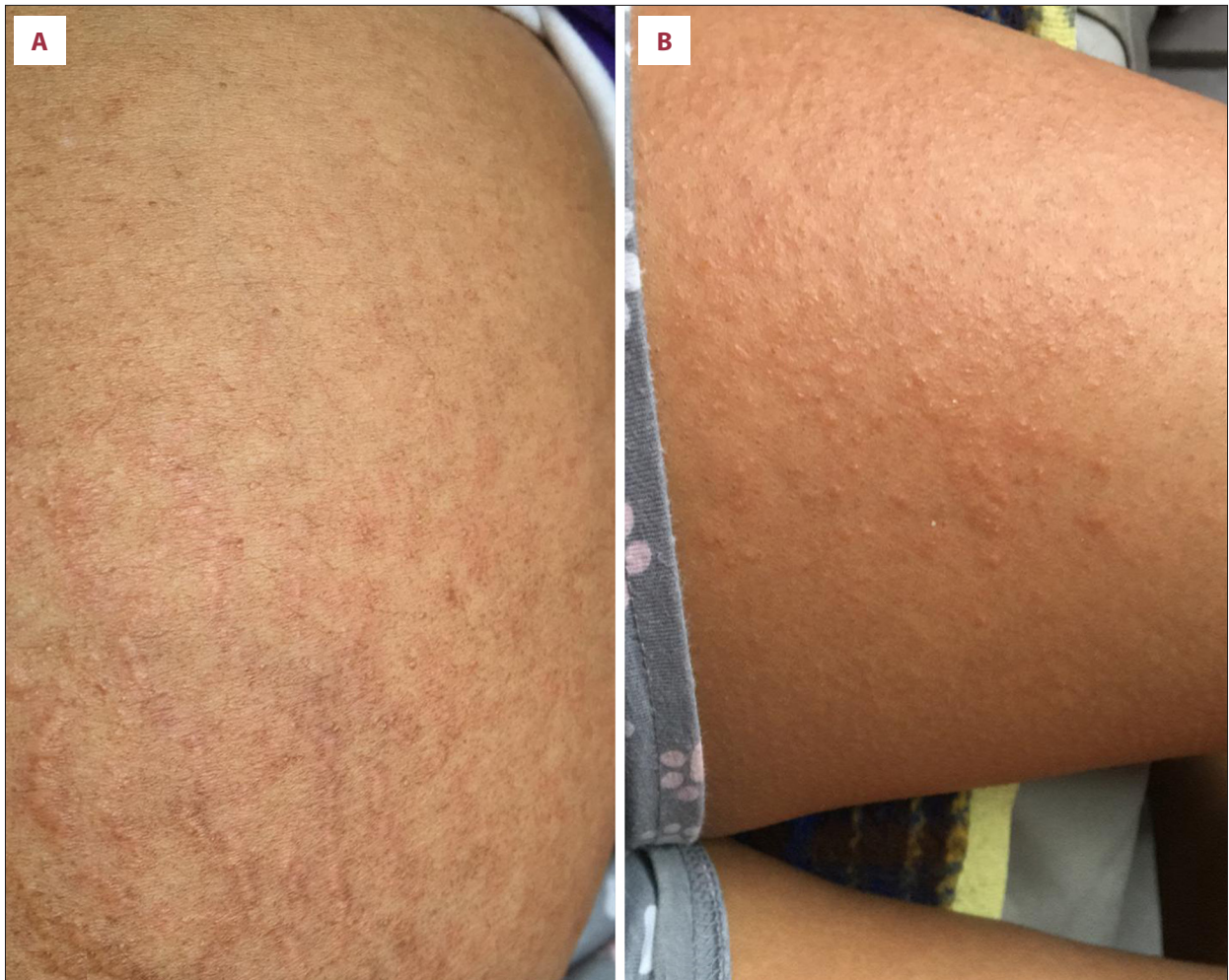A second-trimester ultrasound showed the fetuses at 20.1 and 21 weeks of gestation (7% weight discordance). No detectable structural alterations were identified at that gestational age, and there was normal amniotic fluid in both sacs.

At 29.5 weeks of gestation, the patient reported experiencing odynophagia, earache, and fatigue. She denied having breathing difficulty and fever. She reported that, 7 days earlier, a close relative received a positive diagnosis for SARS-CoV-2.

For the detection of SARS-CoV-2, a nasopharyngeal swab and real-time reverse transcription-polymerase chain reaction (RT-PCR) test was carried out with the GeneFinder COVID-19 plus RealAmp kit, which actively detects the amplification of the RdRp, E, and N genes. This continues to be the recommended protocol of the World Health Organization (WHO). The patient tested positive for the SARS-CoV-2 virus.

Three days later, a fetal ultrasound was performed and did not show any abnormalities. Symptomatic management was established, and the patient remained stable. Nine days later, she presented with disseminated dermatosis predominantly in the abdomen and anterior face of the thighs, characterized by maculopapular lesions and pruritic hives (Figure 1). Laboratory test results showed mixed dyslipidemia without other alterations. Therefore, she was discharged with instructions to monitor her vital signs at home and she was informed of obstetric and respiratory alarm data. The patient noticed a total remission of symptoms, including the rash, 3 weeks after the onset of symptoms.

A control RT-PCR test was performed 1 month later, and the result was negative. A fetal ultrasound performed at the same visit showed the fetometry for twin 1 as 33.3 weeks of gestation (34th percentile), normal umbilical artery and middle cerebral artery Doppler indices, with normal pulsatility



**Figure 1.** Disseminated dermatitis is observed predominantly in the (A) abdomen and (B) anterior thighs characterized by a maculopapular rash with an erythematous base, related to acute SARS-CoV-2 infection in a pregnant patient.

rates and flow present in diastole, and normal amniotic fluid (Figure 2A). The fetometry for twin 2 showed 34.4 weeks of gestation (82nd percentile), normal umbilical artery and middle cerebral artery Doppler, with normal pulsatility rates and flow present in diastole, and normal amniotic fluid. We decided to schedule a cesarean section 2 weeks later, at 36.4 weeks of gestation (Figure 2B).

A cesarean section was performed at 36.4 weeks of gestation because the patient began having uterine activity and both twins occupied a transverse lie. Twin 1 had a weight of 2395 g, length of 44 cm, Apgar score of 9/9, blood type of positive O Rh, and 35 weeks of gestation. Serum antibodies against SARS-CoV-2 in twin 1 showed positive IgG (1.56). Twin 2 had a weight of 2100 g, length of 44 cm, Apgar score of 8/9, blood type of positive O Rh, and 35 weeks of gestation. Serum antibodies against SARS-CoV-2 were negative. Both babies were healthy, with normal metabolic screening test results, and were discharged without complications.

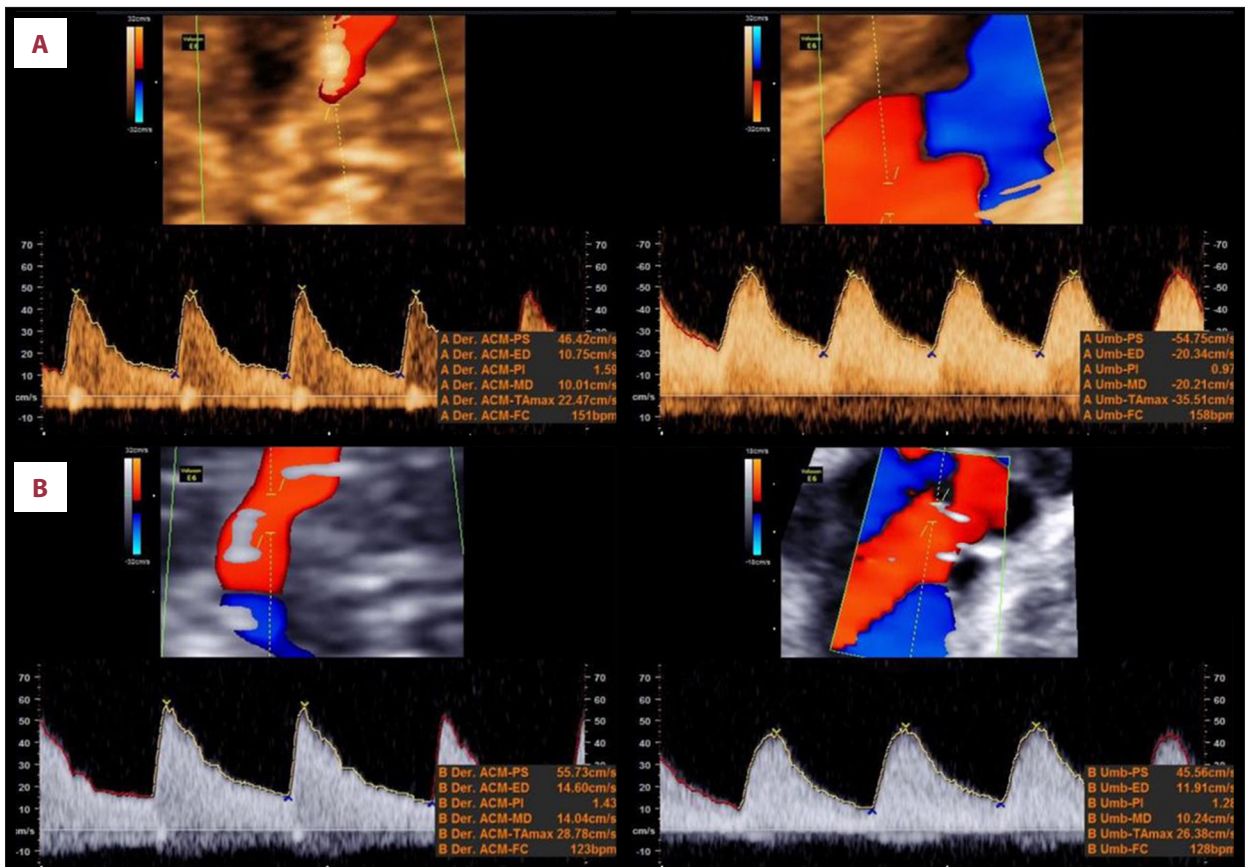
## Discussion

Although the present case agrees with what has previously been described about the association between pregnancy and COVID-19, some data, including the manner in which the pregnancy was conceived, the dermatological manifestations of the SARS-CoV-2 infection, and the serological positivity of 1 of the newborns, are uncommon and, to date, have been seldom reported in the literature in Mexico or elsewhere.

In a cohort of 10 pregnant patients studied by Cao et al, all patients reported having mild COVID-19, no deaths were reported, and 80% of the women delivered by cesarean section [10]; their study results coincide with the clinical characteristics of our present case.

From January to June 2020, the Center for Diseases Control received reports of women of reproductive age being infected by SARS-CoV-2. After adjusting for age, race/ethnicity, and





**Figure 2.** Doppler ultrasound showing diamniotic dichorionic pregnancy. It is important to note that the middle cerebral artery and the umbilical artery have normal values of pulsatility index and flow present in diastole, which translates into adequate transplacental flow. (A) twin 1; (B) twin 2.

medical condition, they found pregnant women were significantly more likely to be admitted to the intensive care unit (aRR 1.5, 95% confidence interval [CI] 1.2-1.8) and receive mechanical ventilation (aRR 1.7, 95% CI 1.2-2.4), compared with non-pregnant women, but their risk of death was similar [11].

An important point to consider is that pharyngeal or nasopharyngeal swab RT-PCR testing is still considered the criterion standard for the diagnosis of SARS-CoV-2 infection. This diagnostic method must be carried out in certified laboratories and under the strict WHO protocols [12,13].

In a retrospective study conducted at the beginning of the pandemic, Chen et al analyzed the clinical, paraclinical, and outcome characteristics of a cohort of 9 pregnant women in Wuhan, China. No differences in clinical presentation or severity were found between this sample and the non-pregnant population, nor was there any evidence of vertical transmission [14]. This contrasts with the findings of the present case, in which in utero transmission of the virus was indirectly evidenced by positive antibody serology in 1 of the neonates.

Mehta et al reported a similar case to ours, in which conception was achieved by in vitro fertilization and it was also a twin pregnancy. Additionally, the presentation of COVID-19 disease was initially mild but progressively worsened until the patient required invasive mechanical ventilation. An emergency cesarean section was performed, both twins were premature, and, as in our case, SARS-CoV-2 infection was registered in 1 baby [15].

In a meta-analysis conducted by Pettiroso et al, 60 articles addressing cases of pregnant women with COVID-19 were reviewed, resulting in a population of 1287 cases of positive SARS-CoV-2 infection. The researchers found that the rate of severe COVID-19 disease in pregnant women approximated that of the non-pregnant women. There were 6 neonatal deaths, 7 stillbirths, and 8 maternal deaths. Nineteen newborns were positive for SARS-CoV-2 by the RT-PCR testing method; however, researchers were unable to elucidate either the time of infection (in utero, during delivery, or postpartum) or the involvement of the infection in the newborns [16].

In a cohort of 15 pregnant patients with COVID-19 in Hubei, China, cough and fever were reported as the most common symptoms, and the researchers concluded that neither pregnancy nor delivery aggravated symptoms in this population. However, in contrast to our present case, no dermatologic manifestations of SARS-CoV-2 infection were described [17].

Some physiological and pathological cutaneous manifestations associated with pregnancy are more frequent than those associated with COVID-19 and deserve mention. They should be considered in a differential diagnosis and can be grouped into 5 categories according to Soutou et al: (1) physiological changes, (2) pregnancy-specific dermatoses, (3) cutaneous infections affecting fetal outcome, (4) intercurrent dermatoses affected by or affecting pregnancy, and (5) adverse effects of topical cutaneous treatments [18].

With the current assessment of cases of COVID-19 experienced during pregnancy around the world, it has been so far proposed that pregnant women are not at a greater risk than the general population. According to Caparros-Gonzales, newborns are affected to a greater extent, so the timely diagnosis of SARS-CoV-2 infection and proper management of the infection in newborns are essential [19].

In a cohort of 64 pregnant patients, in which 69% had severe COVID-19, there was 1 reported case of maternal cardiac arrest and no cases of maternal death. In the cohort, 88% of the women had premature deliveries and up to 94% had cesarean section, as in our case [20].

In August 2020, a case of placental abruption in a woman with a twin pregnancy and diagnosis of COVID-19 was reported. Since the patient had no other risk factors for the abruption [21], this opens the way for conducting further studies to find a relationship between this new virus and this obstetrical condition. In our case, no placental pathology was evident, but it is a very important factor to consider during obstetric examination in the context of this pandemic.

Finally, in Canada, Berthelot et al evaluated an important aspect: the mental health of pregnant patients in the framework of a health emergency such as COVID-19. They concluded that during this pandemic, pregnant women experienced

psychiatric symptoms, such as distress and depression, more often than pregnant women before the pandemic [22]. This may affect not only the mental health of the mother, but also the well-being of the baby.

## Conclusions

Ten months after the beginning of the pandemic, there is no conclusive evidence that pregnant women represent a more or less vulnerable sector than the general population for severe forms of COVID-19. However, in special situations such as the case presented here, in which a multiple pregnancy might exacerbate the natural vulnerability to the acquisition of any infection, timely medical care and close monitoring of pregnant women are especially necessary in the context of the pandemic.

Also, although there are not yet reports that clearly indicate the in utero effects of this virus in the third trimester of pregnancy, timely detection of SARS-CoV-2 by any method (RT-PCR or serum antibodies) in newborns may result in better and earlier medical care that may impact the prognosis of both mother and child. This case report has highlighted the importance of performing a reliable diagnostic test for SARS-CoV-2 infection in patients who present with a skin rash, particularly in pregnant women.

## Statement

The above case has not been entered into any database.

## Acknowledgments

We thank Cecilia Maidé Pinto España for editing the images presented in this report.

## Institution where work was done

The present work was carried out at the National Institute of Respiratory Diseases.

## Conflict of Interest

None.

## References:

1. Secretaría de Salud: Informe Técnico Diario COVID-19 MÉXICO. [https://www.gob.mx/cms/uploads/attachment/file/588328/Comunicado\\_Tecnico\\_Diario\\_COVID-19\\_2020.10.27.pdf](https://www.gob.mx/cms/uploads/attachment/file/588328/Comunicado_Tecnico_Diario_COVID-19_2020.10.27.pdf) [in Spanish]
2. Rajewska A, Mikołajek-Bedner W, Lebdowicz-Knul J, et al. COVID-19 and pregnancy – where are we now? A review. *J Perinat Med.* 2020; 48(5):428-34
3. Schwartz D. An analysis of 38 pregnant women with COVID-19, their newborn infants, and maternal-fetal transmission of SARS-CoV-2: Maternal coronavirus infections and pregnancy outcomes. *Arch Pathol Lab Med.* 2020;144(7):799-805
4. Castro P, Matos AP, Werner H, et al. Covid-19 and pregnancy: An overview. *Rev Bras Ginecol Obstet.* 2020;42(7):420-26
5. Narang K, Enninga EA, Gunaratne MD, et al. SARS-CoV-2 infection and COVID-19 during pregnancy: A multidisciplinary review. *Mayo Clin Proc.* 2020;95(8):1750-65
6. Dashraath P, Wong JLI, Lim MX, et al. Coronavirus disease 2019 (COVID-19) pandemic and pregnancy. *Am J Obstet Gynecol.* 2020;222(6):521-31
7. Chouk C, Litaïem N. Pruritic urticarial papules and plaques of pregnancy. In: *StatPearls.* Treasure Island (FL): StatPearls Publishing. 2020
8. Lehrhoff S, Pomeranz MK. Specific dermatoses of pregnancy and their treatment. *Dermatol Ther.* 2013;26(4):274-84
9. Lawley TJ, Hertz KC, Wade TR, et al. Pruritic urticarial papules and plaques of pregnancy. *JAMA.* 1979;241(16):1696-99
10. Cao D, Yin H, Chen J, et al. Clinical analysis of ten pregnant women with COVID-19 in Wuhan, China: A retrospective study. *Int J Infect Dis.* 2020;95:294-300
11. Ellington S, Strid P, Tong VT, et al. Characteristics of women of reproductive age with laboratory-confirmed SARS-CoV-2 infection by pregnancy status – United States, January 22–June 7, 2020. *Morb Mortal Wkly Rep.* 2020;69:769-75
12. World Health Organization. Use Of Laboratory Methods For Sars Diagnosis. <https://www.who.int/health-topics/severe-acute-respiratory-syndrome/technical-guidance/laboratory/use-of-laboratory-methods-for-sars-diagnosis>
13. Sethuraman N, Jeremiah SS, Ryo A. Interpreting diagnostic tests for SARS-CoV-2. *JAMA.* 2020;323(22):2249-51
14. Chen H, Guo J, Wang C, et al. Clinical characteristics and intrauterine vertical transmission potential of COVID-19 infection in nine pregnant women: A retrospective review of medical records. *Lancet.* 2020;395(10226):809-15
15. Mehta H, Ivanovic S, Cronin A, et al. Novel coronavirus-related acute respiratory distress syndrome in a patient with twin pregnancy: A case report. *Case Rep Womens Health.* 2020;27:e00220
16. Pettiroso E, Giles M, Cole S, et al. COVID 19 and pregnancy: A review of clinical characteristics, obstetric outcomes and vertical transmission. *Aust N Z J Obstet Gynaecol.* 2020;60(5):640-59
17. Liu D, Li L, Wu X, et al. Pregnancy and perinatal outcomes of women with coronavirus disease (COVID-19) pneumonia: A preliminary analysis. *Am J Roentgenol.* 2020;215(1):127-32
18. Soutou B, Aractingi S. Skin disease in pregnancy. *Best Pract Res Clin Obstet Gynaecol.* 2015;29(5):732-40
19. Caparros-Gonzalez RAA. Consecuencias maternas y neonatales de la infección por coronavirus COVID-19 durante el embarazo: Una scoping review. *Rev Esp Salud Publica.* 2020;94(1):e1-9 [in Spanish]
20. Pierce-Williams RAM, Burd J, Felder L, et al. Clinical course of severe and critical coronavirus disease 2019 in hospitalized pregnancies: A United States cohort study. *Am J Obstet Gynecol.* 2020;2(3):100134
21. Kuhrt K. Placental abruption in a twin pregnancy at 32 weeks' gestation complicated by coronavirus disease 2019 without vertical transmission to the babies. *Am J Obstet Gynecol.* 2020;2(3):100135
22. Berthelot N, Lemieux R, Garon-Bissonnette J, et al. Uptrend in distress and psychiatric symptomatology in pregnant women during the coronavirus disease 2019 pandemic. *Acta Obstet Gynecol Scand.* 2020;99:848-55