

Received: 2020.12.04

Accepted: 2021.01.28

Available online: 2021.02.03

Published: 2021.XX.XX

# A Case of Elephantiasis Nostras Verrucosa Secondary to Lymphedema Praecox Complicated by Congestive Cardiac Failure

## Authors' Contribution:

Study Design A  
Data Collection B  
Statistical Analysis C  
Data Interpretation D  
Manuscript Preparation E  
Literature Search F  
Funds Collection G

ADFG 1 **Hamid Sharif Khan**  
AFG 1 **Muhammad Mohsin**  
BCDE 1 **Muhammad Javaid**  
BCEG 2 **Asmara Malik**  
BEFG 3 **Muhammad Shoaib**  
ABEFG 1 **Jahanzeb Malik**

1 Department of Cardiology, Rawalpindi Institute of Cardiology, Rawalpindi, Pakistan  
2 Department of Public Health, National University of Medical Sciences, Rawalpindi, Pakistan  
3 Department of Cardiology, Pakistan Institute of Medical Sciences, Islamabad, Pakistan

**Corresponding Author:** Jahanzeb Malik, e-mail: [heartdoc86@gmail.com](mailto:heartdoc86@gmail.com)  
**Conflict of interest:** None declared

**Patient:** Male, 65-year-old  
**Final Diagnosis:** Elephantiasis nostras verrucosa  
**Symptoms:** Congestive cardiac failure • leg swelling • leg ulcers  
**Medication:** —  
**Clinical Procedure:** —  
**Specialty:** Cardiology • Dermatology

**Objective:** Rare co-existence of disease or pathology


**Background:** In lymphedema, an imbalance in the formation and absorption of lymph causes accumulation of protein-rich fluid in the interstitium of the most gravity-dependent parts of the body. Diagnosis is usually made based on patient medical history and a physical examination showing a typical appearance of the affected body part. Differential diagnosis is confirmed by imaging.

**Case Report:** Primary lymphedema is inherited in through an autosomal dominant pattern. Congestive cardiac failure and non-filarial infections predispose patients to the secondary form of lymphedema, elephantiasis nostras verrucosa (ENV). We present the case of a 65-year-old man with lymphedema praecox complicated by congestive cardiac failure. The patient was experiencing worsening left leg swelling and had a prior history of unilateral leg swelling at puberty. The condition was inherited through an autosomal dominant pattern, as his father, elder brother, and nephew were diagnosed with the same disease. The left leg showed non-pitting edema with indurated, woody skin and lichenification. The right leg had mild pitting edema. There were numerous verrucous folds and cobblestone-like nodules, and plaques and a painless ulcer on the left leg. Laboratory evaluation demonstrated an elevated B-type natriuretic peptide. He was treated with compression stockings and inelastic multi-layer bandaging and was administered limb decongestive treatment. After 1 week of therapy, his swelling had somewhat improved.

**Conclusions:** Various conditions can cause ENV and it can superimpose on any form of hereditary lymphedema. The most effective strategy for this condition seems to be a thorough workup of the underlying cause of the ENV and early intervention.

**Keywords:** Cardiomyopathy, Dilated • Elephantiasis • Lymphedema

**Full-text PDF:** <https://www.amjcaserep.com/abstract/index/idArt/930269>

 1517

 —

 2

 9



## Background

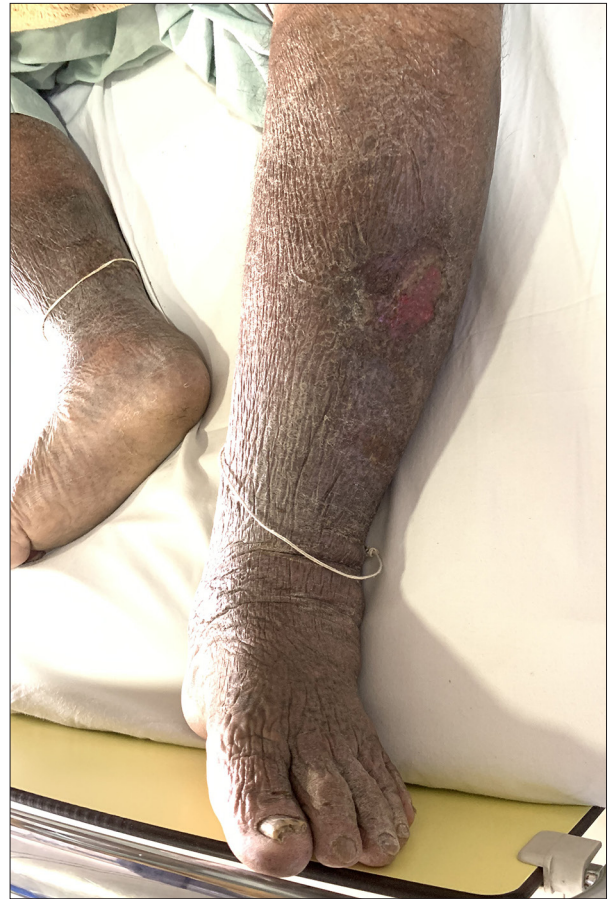Lymphedema is a disorder of the lymphatic channels in the skin that creates an imbalance between the formation and absorption of lymph, causing an abnormal collection of protein-rich fluid in the tissue [1]. Because of this defect in the lymphatic system, patients can experience progressive edema evolving into fibrosis and skin deformities. Lymphedema can be categorized into primary or secondary causes. The primary causes are congenital or idiopathic and the secondary causes are acquired infections, malignancy, heart failure, and certain medical interventions. The estimated prevalence of lymphedema is around 2%, with the highest prevalence related to the secondary causes in developing countries where *Wucheria bancrofti* is endemic [2].

The clinical course of lymphedema is characterized by the chronic accumulation of fluid, macromolecules, and inflammatory cells in the interstitial space, causing fibrosis and adipose hypertrophy; fibrosis can cause non-pitting edema. The clinical staging of lymphedema entails the assessment of the consistency of the skin in terms of the degree of subcutaneous fibrosis and the amount of reduction in fluid volume after 24 h of raising the affected limb. Stage I lymphedema is characterized by the appearance of a sheen on the skin and mild swelling, without evidence of fibrosis, which recedes after limb elevation for less than 24 h. Stage I shows evidence of pitting with applying finger pressure. Stage II lymphedema is defined as the presence of a minimal amount of fibrosis, with skin indentation occurring from finger pressure. However, stage II edema does not disappear after 24 h of limb elevation. The most advanced form of lymphedema is stage III, also called “elephantiasis”. It exhibits major subcutaneous fibrosis, skin firmness, and no pitting of the skin under pressure [3]. Variable presentations of elephantiasis can include ulcerations, warty skin lesions, acanthosis, scales, and fat deposits.

One cause of secondary lymphedema is elephantiasis nostras verrucosa (ENV), a rare form of chronic lymphedema, which causes progressive cutaneous hypertrophy. Physicians need to recognize ENV, its underlying pathophysiology, clinical presentation, and differential diagnoses. Therefore, we present the case of a 65-year-old man with ENV and hereditary lymphedema, which was complicated by congestive cardiac failure.

## Case Report

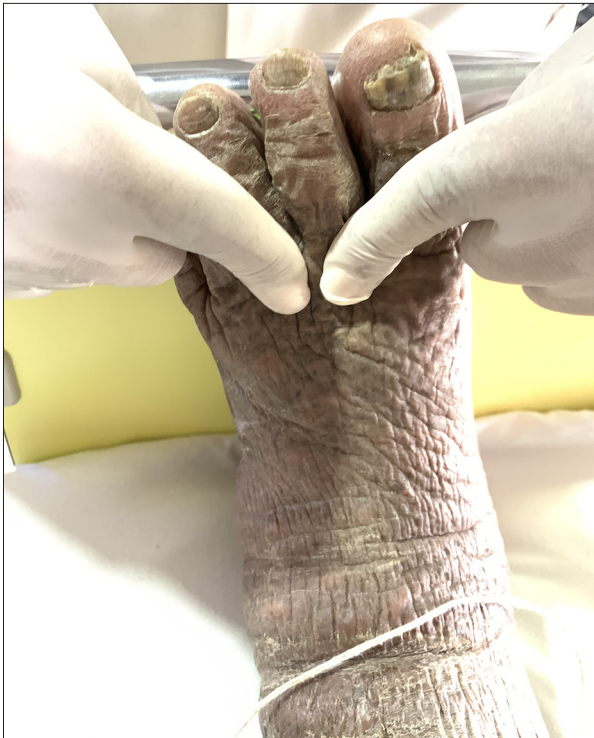A 65-year-old man presented to our hospital’s clinic with a 6-month history of orthopnea and worsening dyspnea on exertion. He also described having worsening leg swelling with painless sores and cellulitis with flaky skin for the past 3 months. His past medical history was significant for chronic left



**Figure 1.** Numerous verrucous folds and cobblestone-like nodules, and plaques and a painless ulcer on the left leg.

leg swelling which started when he was 15 years old. No other comorbid conditions were present, and the patient had no significant travel history. His father, elder brother, and nephew had the same history of chronic massive unilateral leg swelling starting in the teenage years. All of them were diagnosed as having lymphedema praecox.

During physical examination, the patient’s vital signs were blood pressure of 140/100 mm Hg, a regular pulse of 90 beats per min, oxygen saturation of 97% on room air, and a temperature of 36.7°C. The patient’s body mass index was 31.6 kg/m<sup>2</sup>. He had jugular venous distension. The lungs were clear to auscultate, and no additional sounds were heard on cardiovascular examination. The left leg showed non-pitting edema with indurated, woody skin and lichenification, while the right leg had mild pitting edema. There were numerous verrucous folds and cobblestone-like nodules, and plaques and a painless ulcer on the left leg (Figure 1). The Kaposi-Stemmer sign (inability to tent the dorsal aspect of the skin at the base of the second toe) was positive (Figure 2). The temperature of both legs was the same.



**Figure 2.** The positive Kaposi-Stemmer sign.

The results of the laboratory evaluation, including blood count, cardiac enzymes, D-dimer, C-reactive protein, metabolic profile, and thyroid function test were normal. Abnormal values included B-type natriuretic peptide levels of 467 pg/mL (reference range, up to 100). Blood cultures showed no organisms. Chest radiograph images showed scattered pulmonary infiltrate with prominent hilar markings, and the electrocardiogram showed a partial left bundle branch block. Echocardiography showed an ejection fraction of 20% and dilated left and right chambers. There was also global hypokinesia with a thinned left ventricle and mild mitral and tricuspid regurgitation. Doppler sonography did not show any arterial or venous clots. Computed tomography angiography showed normal coronary arteries. The patient was admitted as a working diagnosis for dilated cardiomyopathy and presumed elephantiasis of the left leg. A skin biopsy was consistent with stasis dermatitis, and a diagnosis of ENV superimposed on lymphedema praecox with congestive cardiac failure was confirmed.

The patient began guideline-directed medical therapy for cardiac failure with high dose diuretics including eplerenone 25 mg once daily and furosemide 40 mg every 6 h, and intravenous amoxicillin/clavulanic acid 1.2 g 3 times daily as empirical therapy for cellulitis. His leg was treated with the help of compression stockings and inelastic multi-layer bandaging. The physiotherapist started the patient on limb decongestive therapy. After a week of guideline-directed medical therapy and physiotherapy, his swelling improved and there was

a slight reduction of edema. He was prescribed oral amoxicillin 500 mg (twice per day for 7 days) and a retinoid cream. At the 1-week follow-up visit, the patient was satisfied, despite the treatment showing only a slight improvement. His shortness of breath and orthopnea had subsided. He was referred to a specialized dermatology center for further management.

## Discussion

Hereditary lymphedema, similar to secondary causes of elephantiasis, produces dysfunction of the lymphatic system characterized by an abnormal swelling of the body. Three forms of hereditary lymphedema affecting children are mentioned in the literature: lymphedema praecox accounts for 77% to 94% of cases and typically presents at the onset of puberty as autosomal dominant inheritance; congenital lymphedema presents in 6% to 12% of patients and is subdivided into hereditary congenital lymphedema or Milroy disease and is inherited through an autosomal dominant pattern; and cholestasis-lymphedema, or Aagaenae's syndrome, is inherited through an autosomal recessive pattern [4]. ENV is a secondary form of lymphedema that was first defined by Castellani in 1934 to distinguish elephantiasis tropica from other noninfectious causes of elephantiasis [5]. ENV is a gradual progression of lymphedema and disfigurement of the affected body part as a consequence of recurrent infections or cardiac failure. Our patient represents a case of ENV superimposed on lymphedema praecox due to congestive cardiac failure.

The pathophysiology of subcutaneous changes in ENV is speculative, and it is hypothesized that damage to the lymph channels leads to their microstructure disarray and blockage. The excessive protein-rich fluid then accumulates in the interstitium and subcutaneous tissue, leading to decreased oxygen tension and immune response. Due to the reduced immunity, there is an increased susceptibility to infection. Swelling of the dermis causes the proliferation of fibrous tissue and migration of the smooth muscle cells, thereby causing hardened and indurated skin. This produces a vicious cycle, and the underlying mechanism predisposes the skin to microbial invasion [6].

ENV commonly affects the gravity-dependent parts of the body, specifically the genitalia and lower limbs. Similarly, the upper limbs, abdomen, buttocks, face, and scrotum can be involved. ENV can start at the distal part of the foot and extend to the proximal parts of the limb [7]. At first, there is persistent pitting edema, which, when exacerbated, leads to an inelastic, verrucose, cobblestone-like appearance of the skin. The Kaposi-Stemmer sign, the inability to tent the dorsal aspect of the skin at the base of the second toe, on physical examination in patients with ENV is positive [8]. This sign indicates stage III lymphedema and is attributed to the fibrosis

and thickening of the skin. Over time, ulcers form and become another route for infection.

The diagnosis of ENV is based on patient history and physical examination, with typical cutaneous findings. Various investigations such as skin biopsy, computed tomography, and lymphangiography can be performed to distinguish between the types of secondary lymphedema; in the management of ENV, it is important to address the underlying cause. Lymphostasis can be managed by elastic bandages, compression stockings, and limb decongestion through pneumatic techniques. According to the literature, an elastic bandage is an effective treatment for reduction in swelling, but sometimes it is ineffective. Treatment with diuretics and antibiotics is necessary for reducing edema and controlling infection. In addition, keratolytics and retinoids can help reduce hyperkeratotic plaques [9]. However, an unsatisfactory outcome was obtained in our patient with short-term medical treatment. Surgical interventions are sometimes considered in the management of refractory cases

## References:

1. de Godoy JM, Sanchez AP, Zucchi Libanore D, Guerreiro Godoy Mde F. Adaptations in the treatment of congenital lymphedema centered on the quality of life. *Case Rep Med.* 2014;2014:456060
2. Borman P. Lymphedema diagnosis, treatment, and follow-up from the view point of physical medicine and rehabilitation specialists. *Turk J Phys Med Rehabil.* 2018;64(3):179-97
3. Greene AK, Goss JA. Diagnosis and staging of lymphedema. *Semin Plast Surg.* 2018; 32(1):12-16
4. Sleigh BC, Manna B. Lymphedema. In: StatPearls. Treasure Island (FL): StatPearls Publishing; 2020, <https://www.ncbi.nlm.nih.gov/books/NBK537239/>
5. Castellani A. Elephantiasis nostras (non-filarial elephantiasis). *Proc R Soc Med.* 1934;27(5):519-24
6. Sisto K, Khachemoune A. Elephantiasis nostras verrucosa: A review. *Am J Clin Dermatol.* 2008;9(3):141-46
7. Sarma PS, Ghorpade A. Elephantiasis nostras verrucosa on the legs and abdomen with morbid obesity in an Indian lady. *Dermatol Online J.* 2008;14(12):20
8. Kerchner K, Fleischer A, Yosipovitch G. Lower extremity lymphedema update: Pathophysiology, diagnosis, and treatment guidelines. *J Am Acad Dermatol.* 2008;59(2):324-31
9. Fredman R, Tenenhaus M. Elephantiasis nostras verrucosa. *Eplasty.* 2012;12:ic14

## Conclusions

Various conditions can cause ENV. The most effective strategy for this condition seems to be a thorough workup of the underlying cause of the ENV and early intervention. Usually, the patient history and physical examination provide enough information to make the diagnosis. However, imaging and laboratory tests are essential to differentiate between the causes of lymphedema. Minimizing the edema and increasing the functionality of the affected limb is vital for the successful treatment of ENV. To the best of our knowledge, this is the first reported case of ENV superimposed on lymphedema praecox complicated by congestive cardiac failure. Although numerous treatment strategies were employed, the result was unsatisfactory in our patient.

## Institute Where the Work Was Done

Rawalpindi Institute of Cardiology, Rawalpindi, Pakistan.

## Conflicts of Interest

None.